

# SCIENTIFIC HORIZONS

Journal homepage: <https://sciencehorizon.com.ua>

*Scientific Horizons*, 26(10), 44-50



UDC: 636.2.09: 616.993: 618.39(477)

DOI: 10.48077/scihor10.2023.44

## Pathological changes in aborted fetuses and placental tissue in cows with neosporosis

Bohdan Nyzhnyk\*

Postgraduate Student

National University of Life and Environmental Sciences of Ukraine

03041, 15 Heroiv Oborony Str., Kyiv, Ukraine

<https://orcid.org/0000-0001-5846-8480>

### Article's History:

Received: 15.05.2023

Revised: 26.08.2023

Accepted: 27.09.2023

**Abstract.** The failure to obtain offspring due to abortion causes considerable damage to the dairy industry worldwide, costing millions of USD. *Neospora caninum*, a protozoan parasite of the *Apicomplexa* class, is the causative agent of neosporosis, a disease that leads to abortions or the birth of weak offspring in cows. Therefore, addressing this issue is crucial. The purpose of this study is to describe the pathological changes in aborted fetuses and placental tissue in cows with neosporosis. Macroscopic examination of fetal and placental parts was performed through pathological dissection. The gestation age (days) was determined using the formula:  $68 + 2.25 \times \text{CRL (cm)}$  and/or from historical data. DNA of *N. caninum* was detected by polymerase chain reaction in all fetuses and/or fetal parts of placentas described in the study. It was found that the majority of abortions occurred at 4-5 months of gestation. External examination revealed isolated instances of skin hyperemia and haemorrhages throughout the body. Some fetuses were mummified. Autolysis of the fetus and placental parts was observed in most cases. Placentitis and oedema of the placental tissue were also noted in some cases. Internal examination of fetuses revealed changes in the brain, skeletal muscles, heart, lungs, liver, spleen, and kidneys, in addition to characteristic autolysis. These changes, including grey foci in the brain with a light grey centre, white foci, and multiple white streaks in skeletal muscles and the tongue, can be attributed to typical pathological changes in aborted fetuses with neosporosis. These changes are rare but can impact the determination of the cause of abortion, narrowing down the factors responsible

**Keywords:** cattle; *Neospora caninum*; abortion; macroscopic changes; pathological dissection

### Suggested Citation:

Nyzhnyk, B. (2023). Pathological changes in aborted fetuses and placental tissue in cows with neosporosis. *Scientific Horizons*, 26(10), 44-50. doi: 10.48077/scihor10.2023.44.



Copyright © The Author(s). This is an open access article distributed under the terms of the Creative Commons Attribution License 4.0 (<https://creativecommons.org/licenses/by/4.0/>)

\*Corresponding author

## INTRODUCTION

Abortion remains one of the main challenges in the dairy industry, as reproductive efficiency is crucial, and the failure to obtain offspring can result in significant losses. In many studies, abortion rates range from 5 to 12%, representing a substantial loss of calves and future economic losses (Moore *et al.*, 2021). Infections continue to be the most important cause of abortion in cattle. The infectious agents causing abortions can vary depending on the country in which they occur, with *Neospora caninum* often being referred to as the most common pathogen on an international level (Mee, 2020).

Neosporosis is a disease caused by an obligate intracellular protozoan parasite called *Neospora caninum* (Apicomplexa, Sarcocystidae), which is known to cause abortions and stillbirths in cattle, as described by M. Reichel *et al.* (2020) and D. Lindsay & J. Dubey (2020). Authors like C. Klein *et al.* (2019) established that dogs, coyotes, wolves, and dingoes are definitive hosts of *N. caninum*, becoming infected by ingesting bradyzoites present in tissues of intermediate hosts such as cattle, deer, sheep, buffalo, bison, rodents, birds, and horses, which acquire infection by ingesting oocysts of the parasite through contaminated food or water.

In the study by J. Perotta *et al.* (2021), it is described that *N. caninum* infection in cattle can occur through various routes: horizontal (ingestion of oocysts), exogenous transplacental (ingestion of oocysts by pregnant cows), and endogenous transplacental (reactivation of latent infection in the fetus within the pregnant cow). Transplacental transmission of *N. caninum* is the most efficient method and leads to endemic infections. The endogenous infection cycle in the host population is continuous since infected cows give birth to infected calves, which, in turn, enter the breeding herd and continue to spread the infection.

If a cow becomes infected within the first 100 days of pregnancy when lymphoid tissues are developing, the survival of the fetus is unlikely because infectious agents directly kill fetal cells, leading to resorption or fetal mummification (Donahoe *et al.*, 2015). The paper by M. Reichel *et al.* (2018) noted that during the second and third trimesters, the fetus develops an increasing ability to mount an immune response (IgG antibody production). However, in many cases, this response is inadequate, as abortion is the most common outcome of infection during mid-pregnancy. Infections occurring in the third trimester, after the fetal immune system is nearly fully developed, are more likely to result in the birth of infected but clinically healthy calves. Nevertheless, the birth of uninfected calves can occur very rarely, and fetal death is also a possible outcome.

P. Melendez *et al.* (2020) reported that neosporosis-related abortions in cattle typically occur between the 3rd and 9th months of gestation, with the majority of cases happening during the 4th to 6th months of pregnancy. Aborted fetuses are often found in an autolytic state with the accumulation of serosanguinous fluid in body cavities, but they may also be fresh

or mummified, with no specific pathological changes typically observed. S. Donahoe *et al.* (2015) noted that, in some cases, pathological dissection of the fetus can reveal hydrocephaly, hypoplasia of the cerebellum and brainstem, as well as scattered white or dark foci in the brain, spinal cord, heart, and skeletal muscles. K. Uesaka *et al.* (2018) described that placentitis and changes in the placental cotyledons are most commonly observed in the placental tissue. The pathological-anatomical changes were more pronounced in fetuses during the first and second trimesters of intrauterine development than in the last trimester. This means that the gestational age at the time of abortion affects the degree of damage to the fetus and placental tissues. Infected calves may exhibit symptoms such as hypotrophy, ataxia, hind limb paresis, exophthalmia, scoliosis, hydrocephalus, and spinal cord atrophy.

Neosporosis causes significant economic losses. For example, the financial expenses related to *N. caninum* infection were estimated at 710 USD (438-1043) per dairy cow, and annual economic costs were estimated at 40.5 million USD (24.6-60.3) for Turkey. These losses comprise 67.3% due to abortion, 16.8% due to extended calving intervals, 4.6% due to milk loss, 3.5% due to additional artificial insemination, and 7.7% due to veterinary and diagnostic expenses, as described in the study (Demir *et al.*, 2020). In Brazilian dairy herds, approximately 20% of abortions are linked to neosporosis, resulting in annual losses of approximately 51.3 million USD (Perotta *et al.*, 2021). In Argentina, economic losses are estimated at 33 million USD per year for dairy cattle and 12 million USD for beef cattle (Campero *et al.*, 2023).

Since reproduction is a key element in agricultural production, detecting pathological changes in this context can contribute to the development of effective strategies for neosporosis control and prevention. This, in turn, will preserve herd health and have a positive impact on the economic indicators of the farming industry. The purpose of this study is to describe the pathological-anatomical changes in aborted fetuses and placental parts with detected *N. caninum* DNA in Ukraine.

## MATERIALS AND METHODS

Between 2019 and 2022, 126 cases of abortion were investigated. Of these, 43 cases were attributed to *N. caninum*. A case was defined as an aborted fetus and/or placental part from a cow, resulting in the examination of 36 fetuses and 34 placental parts. Fetuses and placentas were submitted to the laboratory by veterinary practitioners from dairy and dairy-meat cattle farms in various regions of the country.

The dissections and pathological-anatomical examinations of fetuses and placental parts were conducted in the dissection room of "Centre Veterinary Diagnostics" LLC (Kyiv), following the methodology described by J.F. Mee (2016). This methodology encompasses both external and internal examinations, involving the investigation of all organs and organ systems at the

macroscopic level, for both fetuses and placental parts. The gestational age at which the abortions occurred was determined based on data provided by the owners of the aborted animals, in the absence of information, using the formula (1):

$$\text{duration (days)} = 68 + 2.25 \times \text{CRL (cm)}, \quad (1)$$

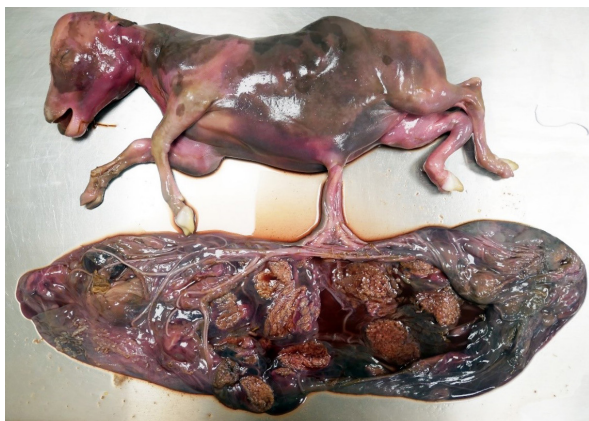where CRL represents the length from the crown to the tail root of the fetus (Mee, 2020).

DNA from *N. caninum* was detected in all cases from fetal organs (including the brain, cerebellum, thymus, heart, lungs, liver, spleen, kidneys, adrenal glands, abomasum, skeletal muscles) and placental parts using the polymerase chain reaction (PCR) method. Amplification reactions were carried out using a commercial test kit from a European manufacturer on the QuantStudio 5 Real Time PCR System (Thermo Fisher Scientific, USA), following the manufacturer's recommendations. Thus, *N. caninum* was determined as the cause of abortion in each of the cases.

Sample collection for genetic-molecular research (PCR method) was performed directly in the dissection room of "Centre Veterinary Diagnostics" LLC during the pathological-anatomical examination. All manipulations with aborted fetuses and placental parts were performed in accordance with the provisions of the Order for scientific institutions conducting research and experiments on animals (Law of Ukraine No. 249, 2012) and the European Convention for the Protection of Vertebrate Animals Used for Experimental and Other Scientific Purposes (European convention..., 1986).

## RESULTS AND DISCUSSION

Based on the medical history and calculations using the formula for gestational age, it was determined that abortions caused by *N. caninum* occurred at the following gestational months: at 4 months in twenty cases, at 5 months in thirteen cases, at 6 months in six cases, at 7 months in two cases, and at 8 months in two cases. Upon external examination of the fetuses, it was found that out of thirty-six fetuses, twenty-nine showed signs of autolysis (Fig. 1), while two were fresh.



**Figure 1.** Autolysis of the fetus and fetal part of the placenta in a cow

Source: photographed by the authors

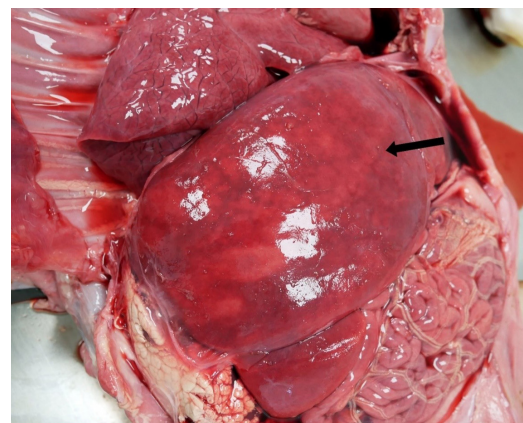
Five fetuses with fetal membranes were mummified (Fig. 2). Moreover, individual findings included skin hyperemia and focal haemorrhages on the skin throughout the body, accumulation of red-coloured fluid under the skin throughout the body in twelve fetuses, and accumulation of gelatinous-like masses under the skin and in skeletal muscles throughout the body in nine fetuses. Corneal opacification was observed in twenty-nine fetuses.



**Figure 2.** Mummified fetus in a cow

Source: photographed by the authors

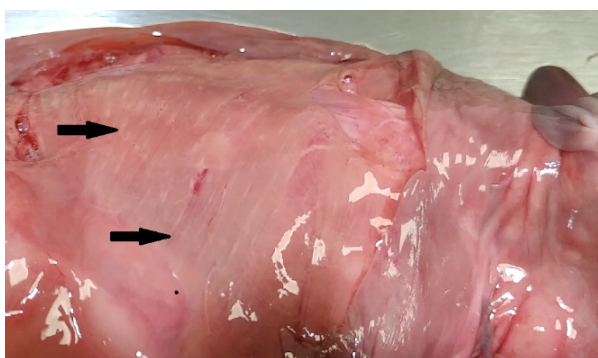During internal examination of the fetuses, watery consistency of the brain was observed in ten cases, and hyperemia in seven cases. Individual findings in the brain included multiple grey-coloured foci with a light grey centre, ranging in diameter from 1 to 4 mm, and hyperemia of the brain's soft meninges. Dark-red fluid was observed in the thoracic and abdominal cavities in twenty-six fetuses. Generalised tissue reddening was noted in eleven fetuses. Heart hyperemia was found in three fetuses. Atelectasis of the lungs was observed in thirty-one fetuses. Interstitial oedema of the lungs – in two fetuses. Hyperemia of the lungs was noted in one fetus. The liver showed flaccid consistency in eleven cases, oedema in two cases, uneven colouration in three cases, and uneven colouration of the liver along with grey-coloured foci with diameters ranging from 2 to 8 mm in three fetuses. Individual findings included icterus of the liver, hepatomegaly, congestive hyperemia, and firm consistency of the liver (Fig. 3).



**Figure 3.** Unevenly coloured liver in a cow fetus (arrow)

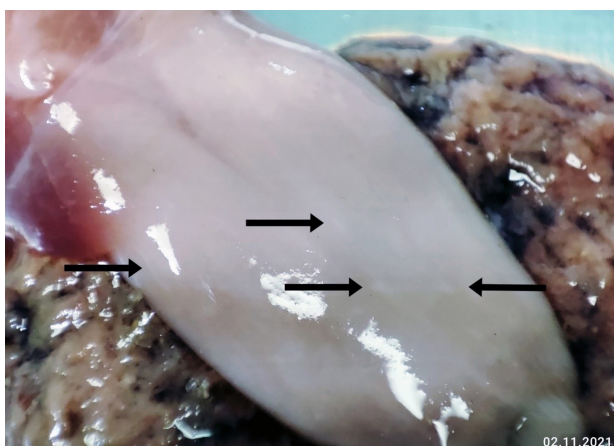
Source: photographed by the authors

Flaccid consistency of the spleen, a smeared pattern, and the presence of dirty-red fluid oozing from the spleen's cut surface were found in eleven fetuses, while oedema was found in four fetuses. Red colouration of the renal capsule and perirenal fat, softening of the renal cortical layer, were identified in eleven fetuses, hyperemia of the kidneys in five, and multiple grey-coloured foci with diameters ranging from 1 to 4 mm in the renal cortex in one fetus. Multiple white-coloured streaks with diameters ranging from 1 to 4 mm in skeletal muscles were observed in two fetuses (Fig. 4), multiple white-coloured streaks ranging from 2 to 6 mm in length in skeletal muscles in three fetuses, and in two fetuses, white-coloured streaks were observed in the tongue (Fig. 5).



**Figure 4.** Multiple white streaks in skeletal muscles of the fetus (arrows)

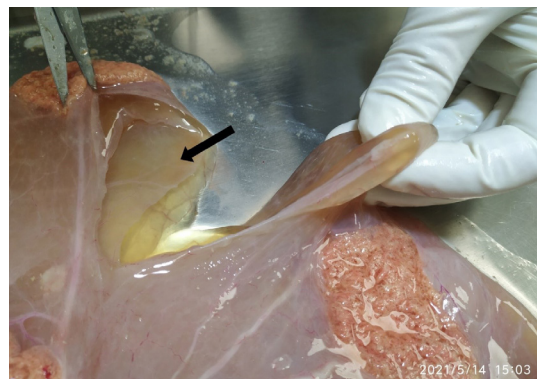
Source: photographed by the authors



**Figure 5.** Multiple white streaks in the tongue of the fetus (arrows)

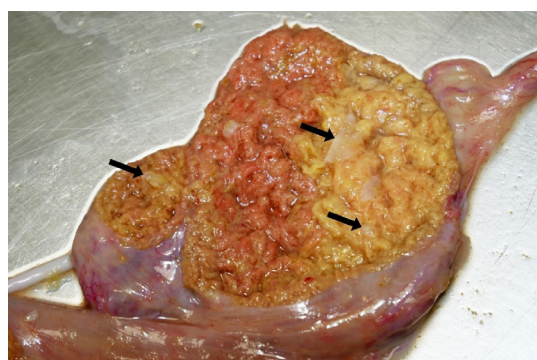Source: photographed by the authors

Autolysis of the placenta was found in nineteen samples, oedema of the placenta (Fig. 6) – in three, fibrinous placentitis – in three (Fig. 7), serous placentitis – in two, foci of chorionic necrosis – in one. Placenta without visible changes was observed in one case.



**Figure 6.** Oedema of the fetal part of the placenta (arrow)

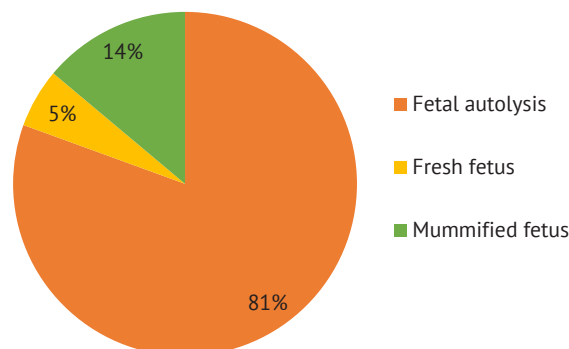
Source: photographed by the authors



**Figure 7.** Fibrinous placentitis. Fibrin on and between chorion fronds (arrows)

Source: photographed by the authors

Thus, in this study, autolysis was present in twenty-nine out of thirty-six fetuses (Fig. 8) and manifested as corneal opacification; accumulation of gelatinous-like masses under the skin and in skeletal muscles or red-coloured fluid under the skin throughout the body; accumulation of dark-red fluid in the thoracic and abdominal cavities; generalised tissue reddening; flaccid liver consistency; flaccid consistency, smeared pattern, and dirty-red fluid oozing from the spleen's cut surface; red colouration of the renal capsule and perirenal fat, softening of the renal cortical layer.



**Figure 8.** Condition of the studied fetuses

Source: photographed by the authors

Autolysis can obscure or distort pathological-anatomical changes and, as a result, negatively affect the determination of the direct cause of abortion. Furthermore, the results of the conducted study indicate a weak manifestation and infrequent occurrence of changes, except for signs of autolysis, in the fetuses and fetal parts of the placenta due to neosporosis. For example, a study of 655 cases of bovine abortions in California found that approximately 20% of examined fetuses showed no specific pathological anatomical changes (Clothier & Anderson, 2016), and any other changes present could have been concealed by autolysis. According to the authors who have investigated this issue, specific changes in fetuses and placentas for neosporosis were also not found (Costa *et al.*, 2021; Nayeri *et al.*, 2022).

Various data indicate that aborted fetuses from cows infected with *N. caninum*, both experimentally (Jiménez-Pelayo *et al.*, 2019) and naturally (Dubey *et al.*, 2017), were predominantly in a state of autolysis of varying severity. However, cases of mummification also occur. Fetal mummification is not a characteristic feature of neosporosis because it occurs far from always and can be a consequence of other factors: viral bovine diarrhoea, leptospirosis, fungal diseases, mechanical factors such as umbilical cord compression and/or torsion, uterine torsion, placental insufficiency, genetic anomalies, abnormal hormonal backgrounds, and chromosomal anomalies (Lefebvre, 2015).

Some sources J. Dubey *et al.* (2017) report cases of hydrocephalus, cerebellar hypoplasia, and hypoplasia of brain tissue. There were no such changes in this study. The pathological-anatomical examination of the fetuses showed that most commonly, the brain had a watery consistency, typically a result of the presence of a large amount of fluid (Njaa, 2012). Hyperemia of the brain was also often detected. Only in isolated cases were multiple grey-coloured foci with a light grey centre, ranging in diameter from 1 to 4 mm, and hyperemia of the brain's soft meninges found. These changes in the brain are histologically consistent with foci of necrosis (Donahoe *et al.*, 2015).

In all cases, atelectasis of the lungs was noted, indicating that the fetus did not breathe, which is normal for aborted fetuses (Ancker & Agerholm, 2010). In some cases, hyperemia and oedema of the interstitial connective tissue of the lungs were found, which are non-specific changes that can result from various factors. Multiple white-coloured foci with diameters ranging from 1 to 4 mm and multiple white-coloured streaks in skeletal muscles and the tongue, ranging from 2 to 6 mm in length, were observed in some fetuses, which are indicative of necrosis. These changes are similar to those described earlier and are very rare (Dubey *et al.*, 2017).

Uneven colouration of the liver, as mostly observed in this study, can be a sign of dystrophic changes. In

addition, grey-coloured foci with diameters ranging from 2 to 8 mm, which can sometimes also be observed in abortions caused by *Listeria monocytogenes*, *Salmonella spp.*, and bovine herpesvirus-1 (BHV-1), were found (Njaa, 2012). Individual findings included oedema, congestive hyperemia, icterus, and hepatomegaly, which can be the result of various factors as they are not commonly mentioned in the context of neosporosis. In most cases, no visible changes were found in the spleen, while in some, oedema was observed. Apart from autolysis, the kidneys showed hyperemia and, in isolated cases, multiple grey-coloured foci in the renal cortex with diameters ranging from 1 to 4 mm, indicating necrosis or inflammation.

It is worth noting that abortion can be entirely triggered by an infection localized exclusively in the placenta and is often the focus of pathological changes rather than the fetus itself. Virtually all infectious agents causing abortion are transported to the pregnant uterus through the bloodstream and therefore initially localise in the placenta, possibly later spreading to the fetus (Ancker & Agerholm, 2010). In the current study, autolysis of the placenta was predominantly observed, making it difficult to evaluate changes in many cases. There were also cases of oedema, serous placentitis, and focal chorion necrosis. Similar changes in the fetal part of the placenta are described in abortions caused by bovine herpesvirus-1 (BHV-1), *Campylobacter fetus*, and *Tritrichomonas foetus* (Njaa, 2012).

In summary, most of the pathological anatomical changes identified in this study can manifest due to the involvement of other infectious agents in fetuses and placentas. Therefore, attention should be paid to this when establishing a preliminary diagnosis, and additional methods of investigation, such as histological and genetic-molecular analysis (PCR method), should be used to establish a final diagnosis. However, among all the findings, the changes in the brain, skeletal muscles, and tongue, which are rarely reported for other causes of abortion, are valuable for establishing a preliminary diagnosis.

## CONCLUSIONS

Any information related to *N. caninum* is important for the development and implementation of measures to combat bovine neosporosis in Ukraine. Considering its impact on the reproduction of cattle worldwide, examining the prevalence of *N. caninum* in the country is crucial. This study established that abortions due to neosporosis occurred between 4-8 months of pregnancy, but most of them were between 4-5 months. When evaluating the condition of fetuses and the fetal part of the placenta, autolysis was observed in most cases. In addition to changes characteristic of autolysis, some fetuses exhibited pathological changes in skeletal muscles, the brain, liver, kidneys, and the fetal part of the placenta, which, based on other sources and our

research, are common in aborted fetuses due to neosporosis and are considered nonspecific. Changes such as grey-coloured lesions with a light grey centre in the brain, white-coloured lesions, and multiple white stripes in skeletal muscles and the tongue can be attributed to typical pathological changes seen in aborted fetuses due to neosporosis. While these changes are rare, they can still serve as diagnostic markers for identifying the cause of abortion.

The association of some pathological changes identified in this study with neosporosis requires further clarification through additional research. Therefore, pathological examinations should be conducted whenever possible. In the future, research can delve

deeper into the pathological changes associated with neosporosis in cows and their impact on aborted fetuses and the placenta. Understanding the mechanisms underlying these changes will help better comprehend the nature of the disease and develop more effective strategies for prevention and treatment.

#### ACKNOWLEDGEMENTS

The author would like to express his gratitude to all the owners of cattle farms who participated in the study for their cooperation and financial support.

#### CONFLICT OF INTEREST

None.

#### REFERENCES

- [1] Ancker, S., & Agerholm, J.S. (2010). *Abortion manual: Guidance on how to manage abortion problems in dairy cattle*. Denmark: Videncentret for Landbrug.
- [2] Campero, L.M., Basso, W., Moré, G., Fiorani, F., Hecker, Y.P., Echaide, I., Cantón, G.J., Cirone, K.M., Campero, C.M., Venturini, M.C., & Moore, D.P. (2023). Neosporosis in Argentina: Past, present and future perspectives. *Veterinary Parasitology, Regional Studies and Reports*, 41, article number 100882. doi: [10.1016/j.vprsr.2023.100882](https://doi.org/10.1016/j.vprsr.2023.100882).
- [3] Clothier, K., & Anderson, M. (2016). Evaluation of bovine abortion cases and tissue suitability for identification of infectious agents in California diagnostic laboratory cases from 2007 to 2012. *Theriogenology*, 85(5), 933-938. doi: [10.1016/j.theriogenology.2015.11.001](https://doi.org/10.1016/j.theriogenology.2015.11.001).
- [4] Costa, L.S. da, Pena, H.F.J., Withoef, J.A., Cristo, T.G. de, Melo, I.C., Oliveira, S., Moura, A.B., & Casagrande, R.A. (2021). Abortion due to *Neospora caninum* in dairy cattle in Southern Santa Catarina State, Brazil. *Acta Scientiarum Veterinariae*, 49. doi: [10.22456/1679-9216.116816](https://doi.org/10.22456/1679-9216.116816).
- [5] Demir, P.A., Eşki, F., & Ütük, A.E. (2020). Estimating the total economic costs of *Neospora caninum* infections in dairy cows in Turkey. *Tropical Animal Health and Production*, 52(6), 3251-3258. doi: [10.1007/s11250-020-02351-1](https://doi.org/10.1007/s11250-020-02351-1).
- [6] Donahoe, S.L., Lindsay, S.A., Krockenberger, M., Phalen, D., & Šlapeta, J. (2015). A review of neosporosis and pathologic findings of *Neospora caninum* infection in wildlife. *International Journal for Parasitology: Parasites and Wildlife*, 4(2), 216-238. doi: [10.1016/j.ijppaw.2015.04.002](https://doi.org/10.1016/j.ijppaw.2015.04.002).
- [7] Dubey, J.P., Hemphill, A., Calero-Bernal, R., & Schares, G. (2017). *Neosporosis in animals*. Boca Raton: CRC Press. doi: [10.1201/9781315152561](https://doi.org/10.1201/9781315152561).
- [8] European convention for the protection of vertebrate animals used for experimental and other scientific purposes. (1986). Retrieved from <https://rm.coe.int/168007a67b>.
- [9] Jiménez-Pelayo, L., García-Sánchez, M., Vázquez, P., Regidor-Cerrillo, J., Horcajo, P., Collantes-Fernández, E., Blanco-Murcia, J., Gutiérrez-Expósito, D., Román-Trufero, A., Osoro, K., Benavides, J., & Ortega-Mora, L.M. (2019). Early *Neospora caninum* infection dynamics in cattle after inoculation at mid-gestation with high (Nc-Spain7)- or low (Nc-Spain1H)-virulence isolates. *Veterinary Research*, 50, article number 72. doi: [10.1186/s13567-019-0691-6](https://doi.org/10.1186/s13567-019-0691-6).
- [10] Klein, C., Barua, S., Liccioli, S., & Massolo, A. (2019). *Neospora caninum* DNA in coyote fecal samples collected in an urban environment. *Journal of Wildlife Diseases*, 55(1), 196-199. doi: [10.7589/2018-02-027](https://doi.org/10.7589/2018-02-027).
- [11] Law of Ukraine No. 249 "On The Procedure for Carrying out Experiments and Experiments on Animals by Scientific Institutions". (2012, March). Retrieved from <https://zakon.rada.gov.ua/laws/show/z0416-12#Text>.
- [12] Lefebvre, R.C. (2015). Fetal mummification in the major domestic species: Current perspectives on causes and management. *Veterinary Medicine (Auckland, N.Z.)*, 6, 233-244. doi: [10.2147/VMRR.S59520](https://doi.org/10.2147/VMRR.S59520).
- [13] Lindsay, D.S., & Dubey, J.P. (2020). Neosporosis, toxoplasmosis, and sarcocystosis in ruminants. *Veterinary Clinics of North America: Food Animal Practice*, 36(1), 205-222. doi: [10.1016/j.cvfa.2019.11.004](https://doi.org/10.1016/j.cvfa.2019.11.004).
- [14] Mee, J.F. (2016). A practitioner's guide to post-mortem examination of an aborted or stillborn calf. *Livestock*, 21(1), 38-43. doi: [10.12968/live.2016.21.1.38](https://doi.org/10.12968/live.2016.21.1.38).
- [15] Mee, J.F. (2020). Investigation of bovine abortion and stillbirth/perinatal mortality - similar diagnostic challenges, different approaches. *Irish Veterinary Journal*, 73, article number 20. doi: [10.1186/s13620-020-00172-0](https://doi.org/10.1186/s13620-020-00172-0).
- [16] Melendez, P., Ilha, M., Woldemeskel, M., Graham, J., Coarsey, M., Baughman, D., Whittington, L., & Naikare, H. (2020). An outbreak of *Neospora caninum* abortion in a dairy herd from the State of Georgia, United States. *Veterinary Medicine and Science*, 7(1), 141-147. doi: [10.1002/vms3.346](https://doi.org/10.1002/vms3.346).

- [17] Moore, D.P., Cantón, G.J., & Louge Uriarte, E.L. (2021). Editorial: Infectious diseases affecting reproduction and the neonatal period in cattle. *Frontiers in Veterinary Science*, 8, article number 679007. doi: [10.3389/fvets.2021.679007](https://doi.org/10.3389/fvets.2021.679007).
- [18] Nayeri, T., Moosazadeh, M., Sarvi, S., & Daryani, A. (2022). *Neospora caninum* infection in aborting bovines and lost fetuses: A systematic review and meta-analysis. *Plos One*, 17(5), article number e0268903. doi: [10.1371/journal.pone.0268903](https://doi.org/10.1371/journal.pone.0268903).
- [19] Njaa, B.L. (2012). *Kirkbride's diagnosis of abortion and neonatal loss in animals*. Oxford: Wiley-Blackwell. doi: [10.1002/9781119949053](https://doi.org/10.1002/9781119949053).
- [20] Perotta, J.H., Freitas, B.B., Marcom, N.N., Pescador, C.A., Pereira, C.C., Locatelli-Dittrich, R., Brum, J.S., & Barros Filho, I.R. (2021). An abortion storm in dairy cattle associated with neosporosis in Southern Brazil. *Revista Brasileira de Parasitologia Veterinária*, 30(2), article number e001821. doi: [10.1590/s1984-29612021045](https://doi.org/10.1590/s1984-29612021045).
- [21] Reichel, M.P., Wahl, L.C., & Ellis, J.T. (2020). Research into *Neospora caninum* – what have we learnt in the last thirty years? *Pathogens*, 9(6), article number 505. doi: [10.3390/pathogens9060505](https://doi.org/10.3390/pathogens9060505).
- [22] Reichel, M.P., Wahl, L.C., & Hill, F.I. (2018). Review of diagnostic procedures and approaches to infectious causes of reproductive failures of cattle in Australia and New Zealand. *Frontiers in Veterinary Science*, 5, article number 222. doi: [10.3389/fvets.2018.00222](https://doi.org/10.3389/fvets.2018.00222).
- [23] Uesaka, K., Koyama, K., Horiuchi, N., Kobayashi, Y., Nishikawa, Y., & Inokuma, H. (2018). A clinical case of neosporosis in a 4-week-old holstein friesian calf which developed hindlimb paresis postnatally. *Journal of Veterinary Medical Science*, 80(2), 280-283. doi: [10.1292/jvms.17-0205](https://doi.org/10.1292/jvms.17-0205).

## Патологоанатомічні зміни у абортіваних плодів та плодової частини плацент корів за неоспорозу

Богдан Юрійович Нижник

Аспірант

Національний університет біоресурсів і природокористування України

03041, вул. Героїв Оборони, 15, м. Київ, Україна

<https://orcid.org/0000-0001-5846-8480>

**Анотація.** Недоотримання приплоду через аборт завдає великої шкоди молочній промисловості у всьому світі і складає десятки мільйонів доларів США. *Neospora caninum* – найпростіший паразит типу *Apicomplexa*, збудник неоспорозу – хвороби, яка у корів проявляється абортими або народженням слабкого потомства, тому варто приділити увагу цій проблемі. Мета даного дослідження – описати патологоанатомічні зміни у абортіваних плодів та плодової частині плацент корів за неоспорозу. Макроскопічне дослідження плодів та плодової частини плацент корів виконувалося шляхом патологоанатомічного розтину. Термін тільності (дні) визначали за формулою –  $68 + 2,25 \times \text{CRL}$  (см) і/або з даних анамнезу. У всіх, описаних у дослідженні, плодах і/або плодових частинах плацент виявлено ДНК *N. caninum* методом полімеразної ланцюгової реакції. Встановлено, що більшість абортів відбувались на 4-5 місяці тільності. За зовнішнього огляду виявлено, поодинокі, гіперемію шкіри та крововиливи на шкірі по всьому тілу. Також деякі плоди були муміфіковані. У більшості випадків відмічали автоліз плоду та плодової частини плаценти. Також в деяких випадках відмічали плацентит та набряк плодової частини плаценти. За внутрішнього дослідження плодів, окрім змін характерних автолізу, у деяких виявляли зміни в головному мозку, скелетних м'язах, серці, легенях, печінці, селезінці, нирках. Такі зміни як осередки сірого кольору з світло-сірим центром в головному мозку, осередки білого кольору і множинні смужки білого кольору в скелетних м'язах та язичі можна віднести до характерних патологоанатомічних змін для абортіваних плодів за неоспорозу. Ці зміни рідко трапляються, але можуть вплинути на встановлення причини абарту, звузивши коло чинників, які його викликають

**Ключові слова:** велика рогата худоба; *Neospora caninum*; аборт; макроскопічні зміни; патологоанатомічний розтин