



UDC 636.034.082.2.4

DOI: 10.48077/scihor1.2024.09

## Dynamics of hypotrophic changes in the morphological formations of the ovaries of heifers of mating age on the 7-9th day of luteogenesis

**Liliya Roman\***

PhD in Veterinary Sciences, Associate Professor  
Odesa State Agrarian University  
65012, 13 Panteleymonyvska Str., Odesa, Ukraine  
<https://orcid.org/0000-0002-4983-5418>

**Vitaly Chorny**

PhD in Veterinary Sciences, Associate Professor  
Odesa State Agrarian University  
65012, 13 Panteleymonyvska Str., Odesa, Ukraine  
<https://orcid.org/0000-0001-5705-1632>

**Nina Dankevych**

PhD in Veterinary Sciences, Assistant  
Odesa State Agrarian University  
65012, 13 Panteleymonyvska Str., Odesa, Ukraine  
<https://orcid.org/0000-0001-8927-5219>

**Alla Kitaeva**

Doctor of Agricultural Sciences, Professor  
Odesa State Agrarian University  
65012, 13 Panteleymonyvska Str., Odesa, Ukraine  
<https://orcid.org/0000-0002-5990-9660>

**Olena Bezalychna**

PhD in Agricultural Sciences, Associate Professor  
Odesa State Agrarian University  
65012, 13 Panteleymonyvska Str., Odesa, Ukraine  
<https://orcid.org/0000-0002-4257-0699>

### Article's History:

Received: 21.09.2023

Revised: 1.12.2023

Accepted: 27.12.2023

**Abstract.** Real-time *in vivo* studies of the physiological or pathological state of the ovaries of cows and heifers are currently relevant because it is the morphological and functional state of the gonads of female cattle that directly affects the effectiveness of biotechnical procedures used in practice: fertilisation, stimulation, and synchronisation of sexual function. The purpose of this study was to find the quantitative and qualitative indicators of the morphological and functional state of the ovaries of Ukrainian red

### Suggested Citation:

Roman, L., Chorny, V., Dankevych, N., Kitaeva, A., & Bezalychna, O. (2024). Dynamics of hypotrophic changes in the morphological formations of the ovaries of heifers of mating age on the 7-9th day of luteogenesis. *Scientific Horizons*, 27(1), 9-19. doi: 10.48077/scihor1.2024.09.



Copyright © The Author(s). This is an open access article distributed under the terms of the Creative Commons Attribution License 4.0 (<https://creativecommons.org/licenses/by/4.0/>)

\*Corresponding author

dairy heifers during the economic year under loose housing conditions of industrial dairy complex. The study used a modified differential diagnosis of the morphometric and functional state of the ovaries at a fixed time of the sexual cycle – from 7 to 9 days after ovulation of the dominant follicle (Day 0 of the cycle). To compare the results of transrectal examination of heifers in different seasons of the year, the technique of visualisation of palpation data *in vivo* was used. 175 heads of heifers of mating age were examined, among which on the 7-9th day of the sexual cycle, 55.42% were found to have a palpable corpus luteum in the ovary according to the stage of development, 26.96% had premature lysis of the corpus luteum, 8.57% had morphological and functional formations on the surface of the ovary, and 9.14% had symptoms of degenerative gonadal pathologies. Subsequently, animals with degenerative changes in the ovaries (follicular kytosis) did not take part in the study. The remaining heifers had ovaries with symptoms of in-depth hypotrophic changes in the tissues (30.00%) or signs of premature lysis of the corpus luteum (33.33%). During the economic year, a pronounced dynamics in the growth or decrease of hypotrophic phenomena in ovarian tissues was noted; the best indicators of morphometry and functional activity of heifers were observed in the warm season, which indicated a considerable effect of fresh air and solar insolation on the sexual function of heifers of mating age. It was found that the level of fertility of heifers during the year (an average of 40.02%) indicated the presence of errors in the technology of growing replacement stock in an industrial enterprise. The findings can be useful for optimising the schemes of hormonal synchronisation of the sexual cycle of replacement heifers and for the correct selection of hormonal therapy in case of symptoms of decreased sexual activity

**Keywords:** heifers; sexual cycle; corpus luteum; morphological and functional state; polymorphism; hypogonadism

## INTRODUCTION

Decrease in fertility levels of dairy cows is an urgent problem in modern dairy farming. The infertility of the dairy herd substantially affects the profitability of dairy production, which is noted in numerous studies by Ukrainian and Western European authors. Thus, according to Ukrainian researchers, the prevalence of infertility in the dairy herd can reach 45-49%, and in 5-76% of cases, pathology of reproductive organs is the reason of sexual function disorders. According to O.O. Borshch *et al.* (2020), 53% of gynecological diseases were diagnosed with the persistence of corpus luteum, 42% – with ovarian hypofunction, and 5% – with cystic lesions of the gonads. A sufficiently long period of heifers until they reach physiological (economic) maturity is a biological feature of cattle as a type of productive animal. During this period, in industrial conditions young animals' organism is exposed to heterogeneous harmful factors, which can negatively affect the development and further functioning of gonads (Bors *et al.*, 2018; Bors & Bors, 2020).

It is well-known that the ovaries of heifers are characterised by essential polymorphism, which is associated with a significant physiological conditions (pregnancy, childbirth and the postpartum period). According to O.O. Borshch *et al.* (2020), A. Channo *et al.* (2022), the size of the ovaries in the follicular stage of the sexual cycle ranges from 2.0×1.5×1.5 cm to 4.0×3.0×3.0 cm. Furthermore, researchers point to high variability in heifer ovarian weight, which depends on the presence of the corpus luteum and the stage of its development or regression. Thus, according to L.H. Yevtukh *et al.* (2022), in the presence of the corpus luteum the ovary weight averaged 4.95-7.25 g, and in the absence of the corpus luteum – 4.78-4.98 g. According to transrectal palpation, these organs are oval in shape, with a firm elastic

consistency (Szelényi *et al.*, 2019). The findings obtained by R. Alvarez *et al.* (2023) suggest that the physiological and clinical state of the gonads during the phases of the physiological sexual cycle or gonadopathy of various etiology is understudied. The author states that this distorts the picture of the morphometry and linear dimensions of the cow's ovaries. The data varies considerably and depends on both the research methods (*in vivo* or *postmortem*) and the development of follicles and corpora lutea.

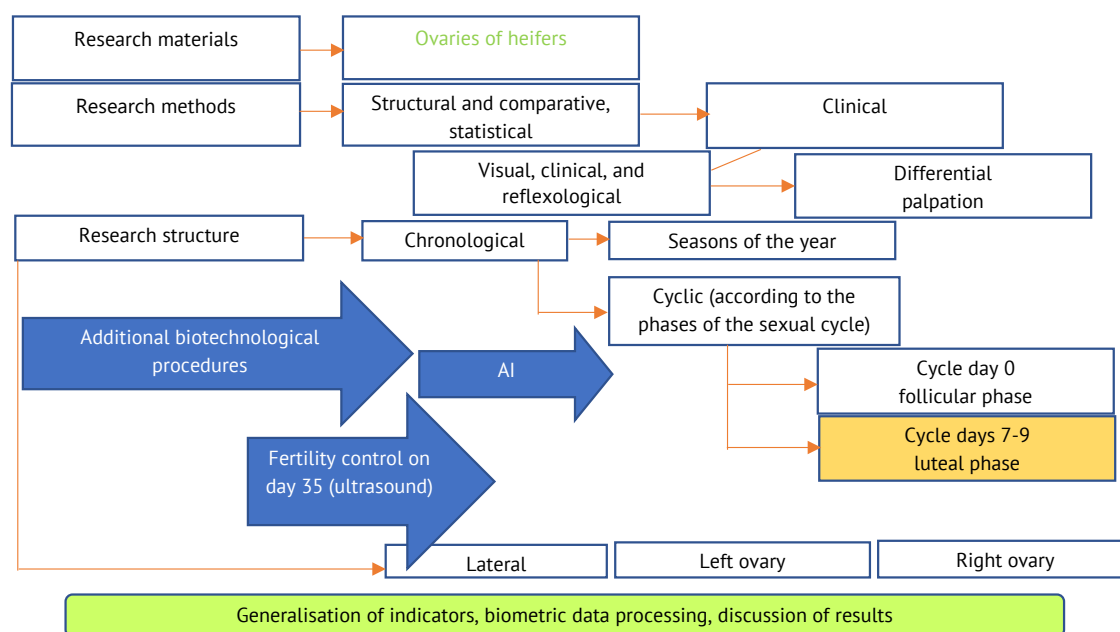
In cases of gonadopathy, F.X. Donadeu *et al.* (2020) found considerable deviations from normal morphology due to pathological formations, including follicular and luteal cysts, polycystic disease, etc. According to O.A. Baban *et al.* (2021), a decrease in the size of the ovaries of cows may be associated with hypotrophy, i.e., a decrease in the size of the cells of the tissues of the cerebral and cortical layers or hypoplasia. B.M. Jaśkowski (2019) explains this phenomenon by a decrease in the number of cells due to functional formations of different phases of the cycle, namely follicular or luteal. According to A.M. Getahun *et al.* (2021), there are no criteria for the differential diagnosis of these pathological phenomena in gonadal morphology at the macro level, which is determined by significant differences in the diagnosis of hypotrophic changes in the ovaries of cows, in particular, heifers of breeding age.

S.Y. Peng *et al.* (2020) provide signs of ovarian hypofunction that are used as diagnostic criteria for this pathology. This makes contradictory recommendations for the prognosis of pathological conditions of the gonads and methods of prevention and therapy of gynecological diseases. According to V. Rottgen *et al.* (2020), ovarian hypofunction is common among 10-68% of infertile cows and is characterised by anaphrodisia, normal ovarian size, reduce in vesicular follicles or their absence.

The polymorphism of gonads of heifers of mating age has been understudied, despite the functional influence of these genital organs on the productive characteristics of dairy cows during the reproductive use of females. That is why the purpose of this study was to determine the prevalence of hypotrophic ovarian changes on the 7-9th day of the sexual cycle of heifers of mating age during the year in different seasons.

## MATERIALS AND METHODS

The study was conducted in 2021-2022 years. Animals were kept in loose housing conditions in an industrial-type dairy complex, which was part of agricultural holdings in the south of Ukraine (Odesa region), on a stock of Ukrainian red dairy heifers ( $n=175$ ), which were examined before being put into groups for artificial insemination when the achievement of zootechnical parameters of breed standards



**Figure 1.** General methodological scheme of examination of the *in vivo* ovaries of heifers of mating age

**Notes:** fixed day of the study of the *in vivo* ovarian morphology for all examined heifers; AI is artificial insemination

**Source:** developed by the author

The conditions of maintenance of heifers met the requirements of current standards and were fed a mixed complete diet twice a day per the zootechnical standards for the content of the main ingredients. The animals were kept in zero grazing conditions. The animals were kept without pasture. A special fixing machine was used during the biotechnological procedures and transrectal examination, and no pain or damage was caused to any animal, following the applicable requirements. The different number of animals in the research and production experiment is explained by the regrouping of animals, their transfer to other divisions of the enterprise, and breeding sales to the public during the business year.

Only clinically healthy mature heifers with a live weight of 355-370 kg took part in the study. All cattle on the farm were covered by veterinary support and an immunisation programme against infectious diseases, which was pursuant to current veterinary guidelines. After transrectal examination, heifers without clinical contraindications and symptoms of gynecological diseases were transferred to the reproduction group, where on Day 0 of the sexual cycle artificial insemination was

performed according to the recto-cervical method with deconserved semen of foreign-bred red and white Holstein bulls in accordance with the breeding plan of the farm. 35 days after AI all heifers that did not show signs of sexual arousal during this time pregnancy was diagnosed by ultrasound scanning (using the KXV1 Kaxin device, made in China). The inseminated animals were accounted using the farm's computer database (Dairy Plan).

The innovation of the study consisted of several stages: 1 – using a fixed term for palpation of the ovaries of heifers of mating age in the luteal phase of the sexual cycle, when morphologically there are of a functionally active corpus luteum; 2 – the use of visualisation of palpatory data with a differential modified method of transrectal diagnosis of the ovaries of heifers (Sidashova *et al.*, 2020). Furthermore, the scientific basis for using the modified palpation technique was the anatomical features of heifer gonad development, namely, their essential polymorphism (Sidashova, 2019). Therefore, as a marker indicator of the severity of hypotrophic changes in ovarian tissues, the *in vivo* study considered not only linear sizes, but also the dynamics of corpus luteum formation, i.e., the

assessment of ovarian luteogenesis function at a fixed time of the luteal stage of the sexual cycle. During the study, the following indicators of palpation diagnostics were used (the abbreviations used hereinafter in the text, for all tables and diagrams):


- absence of morphological and functional formations on the surface of both ovaries, hypogonadism, severe hypotrophic changes in ovarian tissues (absence of CL – corpus luteum);

- presence of a functional corpus luteum on the surface of one of the ovaries with linear dimensions close to the species norms (CL);

- presence of a functional corpus luteum on the surface of one of the ovaries with linear sizes approaching the highest limit of the species norm and characterising high physiological quality of luteogenesis (CL+);

- presence of a non-functional corpus luteum on one of the ovaries, which has characteristic tactile signs of atresia and luteal cell disintegration, i.e., premature lysis of corpus luteum (CL lysis).

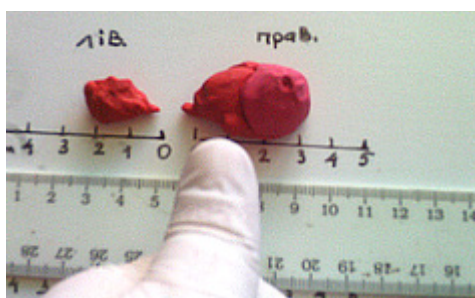An example of the use of the method of visualisation of palpation data for assessing the physiological and morphological state of the ovaries of heifers is presented in Figures 2-4.



**Figure 2.** Application of palpation data visualisation technique to assess the morphological and functional state of heifer ovaries

**Notes:** real-time ovarian models demonstrate the method of measuring linear gonadal size with comparison of data by the size of the researcher's finger *in vivo*, with an assessment of the depth of tissue hypotrophy symptoms

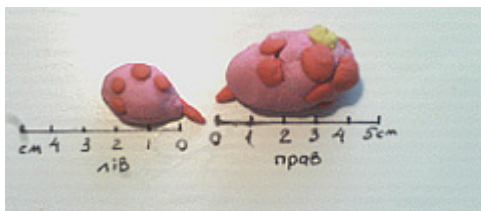
**Source:** developed by the author



**Figure 3.** Ovarian morphometry of heifers

**Notes:** demonstration of palpatory assessment of ovarian morphometry in heifers using the method of visualisation of *in vivo* rectal diagnostic data

**Source:** developed by the author of this study



**Figure 4.** A model of heifer ovaries with morphometry close to the species norm

**Notes:** the ovaries are in transition to the active follicular phase (palpable lysed corpus luteum of the previous cycle and several antral immature follicles, less than 1 cm in diameter)

**Source:** developed by the author of this study

Apart from the chronological structuring by seasons (winter, summer, and transitional) of keeping heifers of mating age on the farm, the lateral structuring of gonads as paired organs was also applied. The left- and right-sided location of morphological and functional ovarian formations was considered, which significantly increased the accuracy of comparison of palpation parameters of each cows.

All experiments were conducted following the modern methodological approaches, requirements and standards that follow DSTU ISO/IEC 17025:2005 (2006). Animal husbandry and all manipulations were performed according to the provisions of the Procedure for conducting tests and experiments on animals by scientific institutions (Law of Ukraine No. 249, 2012), and of the European Convention for the protection of vertebrates used for experimental and other scientific purposes (1986).

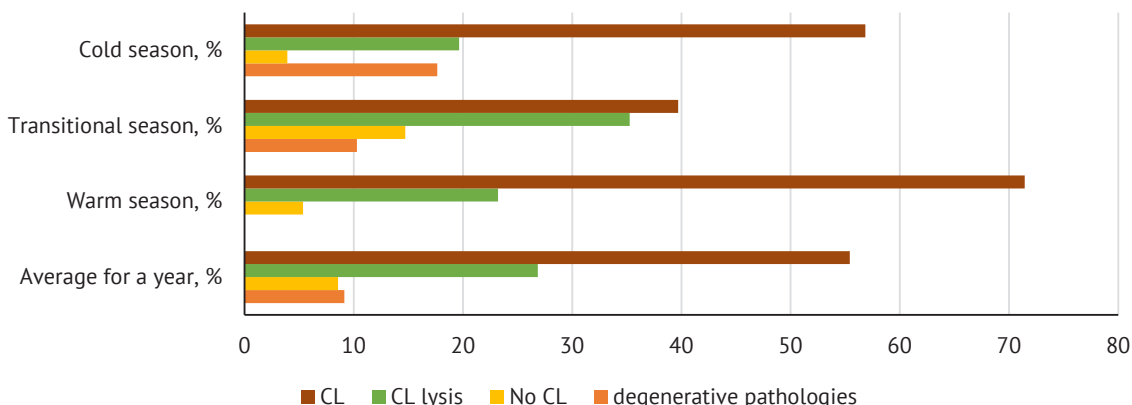
## RESULTS AND DISCUSSION

The use of sequential procedures for differential palpation for each cows, considering the specific features of tactile perception of data, with the additional introduction of a technique for visualising rectal examination indicators using ovarian models in real time, helped to obtain a chronological seasonal profile of the morphology of the existing gonadal pathology of the livestock examined *in vivo*. The results of differential palpation diagnostics on Days 7-9 of the



ovarian sexual cycle of 175 heifers of mating age during different seasons of the 2021-2022 business year

showed the following morphological and pathological profile (Fig. 5).



**Figure 5.** Morphofunctional/morphopathological profile of data on diagnostics of the ovaries of heifers on Days 7-9 of the sexual cycle in different seasons of 2021-2022, n=175


Source: developed by the author

The *in vivo* study of heifer ovaries showed that only 55.42% of females on Days 7-9 after ovulation of the dominant follicle had a functional luteal formation (corpus luteum), the morphometry of which corresponded to the species norm (Fig. 6). 44.58% of heifers' sexual cycles in 7-9 days ended in gonadopathies with various symptoms: cystic degeneration of follicles – 9.14%; lysed corpus luteum with typical signs of atresia – 26.96%; absence of functional formations on the ovarian surface with signs of severe organ hypotrophy – 8.57% (Fig. 7).



**Figure 7.** Ovaries of a 15-month-old heifer with signs of hypotrophic changes in the cortical and follicular layers

Source: developed by the author



**Figure 6.** Profile of morphometric and morphofunctional parameters of the palpable diagnostics of heifers' ovaries at a fixed time of the luteal phase of the sexual cycle (Days 7-9)

**Notes:** 1) absence of CL, several antral follicles, normal ovarian size; 2) CL of the right ovary of satisfactory quality, hypogonadism of the left ovary; 3) severe hypogonadism of both ovaries, absence of morphological and functional formations

Specifically, a substantial seasonal dynamic in the development of various functional or pathological conditions of heifer ovaries was established. Hypotrophic symptoms were observed most often in the transitional seasons of the year (spring-cold autumn), namely, in 66.67% (absence of CL) and 51.08% (premature CL lysis) of cases. A significant number of cases of hypoluteogenesis of ovarian tissues are noteworthy, in which, due to hypotrophic changes, premature atresia of the corpus luteum occurs by Days 7-9 of the cycle, which was already functioning in the first days of formation. The data of gonadopathies with degenerative tissue damage (single cysts or polycystic disease) were excluded from further analysis, and only the species norm and hypotrophic ovarian changes were considered, as presented in Table 1 (n=159).

**Table 1.** Profile of the morphological state of heifer ovarian luteogenesis on Days 7-9 of the sexual cycle according to differential palpation diagnostics, n=159

Indicators	Seasons, surveys						Total/average	
	Winter		Transitional		Warm		Heads	% (M±m)
	Heads	%	Heads	%	heads	%		
Number of animals	42	26.42	61	38.36	56	35.22	159	100.00
CL	30	30.63	27	27.84	40	41.24	97	33.34±4.05

Table 1. Continued

Indicators	Seasons, surveys						Total/average	
	Winter		Transitional		Warm		Heads	% (M±m)
	Heads	%	Heads	%	heads	%		
CL lysis	10	21.28	24	51.06	13	27.66	47	33.33±9.05
Absence of CL	2	3.33	10	66.67	3	20.00	15	30.00±18.95

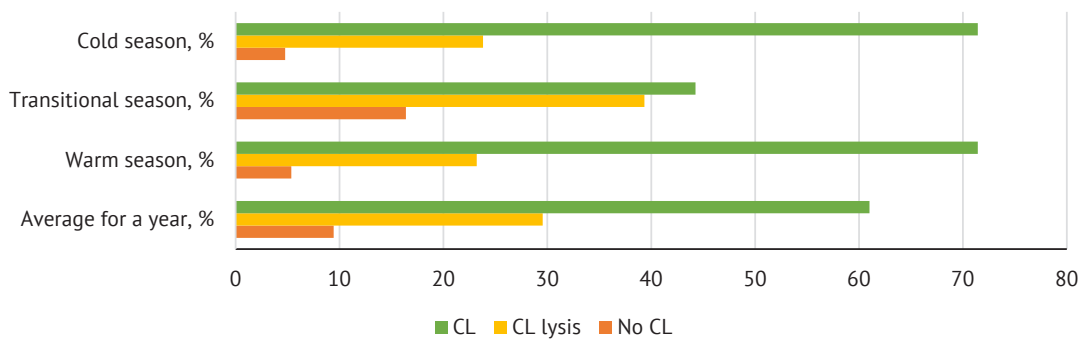
**Notes:** \* and \*\* – explanations in the text (hereinafter – for all tables and diagrams)

**Source:** developed by the author

Observations during the year showed that in August the clinical condition of the ovaries of heifers were divided approximately equally, namely functional corpus luteum of the ovary on Days 7-9 day of the sexual cycle (33.34%) and those showing hypotrophic changes in ovarian tissues at the same time, specifically with pronounced signs of hypotrophy and lack of corpus luteum formation (30.00%) and with symptoms of premature lysis of the corpus luteum due to changes in the blood supply of the ovaries (33.33%) ( $P>0.05$ ). The absence of essential correlations between the data indicates a considerable number of paratypical factors that affect

the process of ovarian luteogenesis of heifers of mating age in industrial production.

Specifically, significant differences in the number of heifers with severe ovarian hypotrophy in summer and transitional seasons indicate a substantial impact of climatic conditions, namely the temperature factor, on the sexual function of heifers (the number of cases of absence of the corpus luteum in winter is 20 times less than in spring and autumn months). Graphically, the dynamics of ovarian hypotrophic changes in different seasons of the year is presented in the diagram (Fig. 8).



**Figure 8.** Dynamics of hypotrophic changes in luteal formations of heifers' ovaries on Days 7-9 of the sexual cycle (2021-2022), n=159

**Source:** developed by the author

The substantial impact of seasonal factors on the ovarian luteogenesis of heifers of mating age prompted a more detailed consideration of the morphology of corpus luteum, which had clear functional characteristics.

The dynamics of the physiological process of luteogenesis in heifers of mating age in different seasons of the year, characterised by high-quality corpus luteum, is presented in Table 2.

**Table 2.** Results of differential palpation assessment of the quality of functional ovarian corpus luteum on Days 7-9 of the reproductive cycle in heifers of mating age, n=74

Indicators	Presence of CL				All functional CLs, % (M±m)	
	incl. CL		incl. CL+		heads	%
	heads	%	heads	%		
Number of animals	49	100.00	25	100.00	74	100.00
Periods: Winter	12	24.49	13	4.00	13	17.57
Transitional	16	21.21	21	20.00	21	28.38
Summer	21	42.86	40	76.00	40	54.05

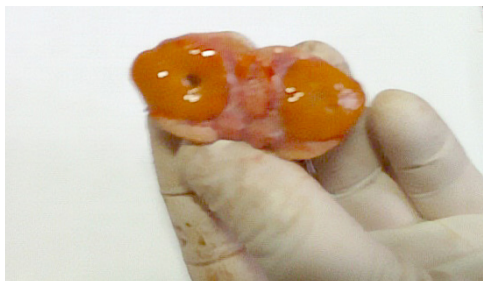**Source:** developed by the author

According to the study, the highest number of high-quality corpora lutea, i.e., the least signs of hypoluteogenesis due to hypotrophic changes in the

follicular and cortical tissues of the ovaries, was observed in the summer (76.00% of all detected functional active corpora lutea). The winter period showed

the worst results in terms of the quality of corpora lutea on Days 7-9 of development in heifers of mating age: only 4.00% of quality quality yellow bodies were found, which indicated a violation of haemodynamics in the gonads, a decreased vitality of cells and hormo-

nal activity of ovaries. Figure 9 presents the ovary of a clinically healthy 15-month-old heifer with a well-developed corpus luteum on Day 9 after ovulation. In palpation diagnostics, these corpora lutea have characteristic morphometric and tactile features.



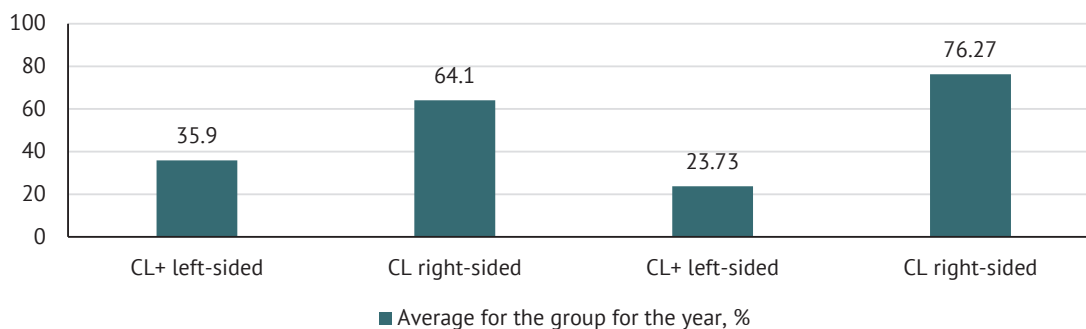
**Figure 9.** Heifer ovary with a well-developed corpus luteum of the sexual cycle

**Notes:** a small physiological cavity is visible inside the temporary gland in the dissection

**Source:** developed by the author of this study

During the study, the ovaries of heifers were observed as a paired organ, and the hypotrophic phenomena in

the gonads was determined according to lateral localisation. The data obtained are presented in Figure 10.



**Figure 10.** Dynamics of lateral localisation of functional corpora lutea on Days 7-9 of development in heifers in different seasons of 2021-2022, n=98

**Source:** developed by the author

The analysis of the fertility rate of heifers of mating age in the farm, presented in Table 3, suggests that on

average for the year the total fertility of heifers was 40.02% of all inseminations (P>0.05).

**Table 3.** Effectiveness of artificial insemination of heifers of mating age during the business year, n=558

Season	AI* of heifers performed, total		Became pregnant (M±m)		incl. of the 1 <sup>st</sup> AI, %	incl. from the 2 <sup>nd</sup> and more AIs, %
	heads	heads	heads	%		
Winter	60	20		33.33	39.00	31.11
Transitional	111	51		45.55	41.14	48.03
Warm	387	151		31.02	39.91	29.98
Total for the year	558	222		36.63±4.51*	40.02±0.62**	36.37±5.84**

**Note:** \* - \*\* -  $\hat{\sigma}=1.074$ ; CV=2.684; td=0.743; P>0.05

**Source:** developed by the author

The absence of essential connections between the indicators suggests a considerable impact of economic factors on the effectiveness of reproduction, while there is a tendency to increase the fertility of heifers of mating age in seasons with more comfortable temperatures for cattle, namely in spring and

autumn, when the overall level of pregnancy increased to 45.55%, and by repeated inseminations – to 48.03%. The applied methodological approach to the differential palpation of the morphological and functional *in vivo* structures of the ovaries of heifers of mating age increases the predictability of biotechnological

procedures for the reproduction of dairy cattle and the selection of adequate schemes for the prevention and treatment of hypotrophy of the gonads of cows.

The observed phenomenon of heterogeneity of the morphological structure of the corpora lutea of the heifer's ovaries by differential palpation *in vivo*, has become an opportunity to explain the pathogenesis of hypotrophic changes in tissues due to sclerotisation of the walls of blood vessels, both arterial and venous, which was histologically confirmed by O.A. Baban *et al.* (2021). Microanatomical examination of the ovaries of heifers with symptoms of anaphrodisia revealed a characteristic decrease in the density of follicular cells in the primary follicles around the oocytes and the formation of gaps between them. The appearance of such formations was explained by a decrease in the secretory activity of follicular cells. According to L.H. Yevtukh *et al.* (2022), the phenomena of follicular cell detachment and destruction with their collagenisation are associated with the processes of follicular atresia against the background of venous hyperaemia and fatty infiltration. S. Dhara and M. Sharma (2020) observed comparable changes in 30-66% of follicles with signs of atresia.

H.P. Hryshchuk *et al.* (2023) noted that the pathogenesis of the formation of basophilic inclusions in the form of droplets near the layer of vesicular follicles is still unclear. E. Dirandeh and J. Ghaffari (2018) found that the cow ovarian medulla in hypofunction was represented by connective tissue elements and permeated with a great number of blood vessels of different diameters. Collagen fibre formation was observed in these vessels, which could lead to a decrease and loss of their elasticity, and therefore the function of normal haemodynamics and nutrition of ovarian tissues. J. Ma *et al.* (2022) conducted pathomorphological studies of the ovaries of cows with hypofunction, with a history of infertility and anaphrodisia. The authors found a range of deviations from the normal morphology of the luteal phase of the cycle, namely: no functionally active corpus luteum, atretic corpus luteum with follicular cell remnants, a decrease in the number of follicular cells and their layers in vesicular follicles, and the formation of collagen fibres in blood vessels.

The present study experimentally proved the expansion of the scope of palpation diagnostics of the morphological and functional state of the ovaries by applying the transrectal data visualisation technique and using a fixed day of the sexual cycle as the palpation period. This approach made it possible to anatomically substantiate palpable indicators and their connection with the specific features of gonadal morphometry *in vivo*. In F.S. Lima *et al.* (2019), the shape and consistency of the gonads were normal in heifers with ovarian hypofunction. Real-time research contradicts these findings. It is probable that the difference in the appearance and structure of organs *in vivo* compared to pathological specimens should be taken considered.

A range of microanatomical studies have reported observations of premature or delayed atresia of vesicular follicles on Days 12 and 15 of the estimated sexual cycle *in vivo*. The experiments performed on a fixed day of the spontaneous sexual cycle interpreted these findings, due to numerous cases of premature corpus luteum atresia by Days 7-9, which can be explained by the development of hypotrophic changes in ovarian tissues. V. Rottgen *et al.* (2020) suggest that there are several mechanisms for the development of pathological phenomena in the ovaries of heifers in the early stages of development of preimplantation zygotes, namely: neurohumoral disorders, especially the synthesis of progesterone and luteotropic hormone; latent endometrial inflammatory processes and possible, yet accounted reasons.

The observed folding of the follicular layer, detected on histological preparations of ovarian tissues from heifers with gonadal hypofunction, is explained by the fact that the inner follicular cells lose their ability to secrete, while the basal cells secrete in the intervals between them. In such follicles, the theca layer is thinned due to a decrease in the density of theca cells. F.S. Lima *et al.* (2019) also observed detachment of follicular cells and their free location in the follicular fluid, destruction of oocytes and follicular cells with the formation of pyknotic nuclei. Such processes indicate a loss of functional capacity of the organ. Using a modified method of palpation diagnostics, the studies revealed clinical conditions of significant gonadal tissue hypotrophy in heifers *in vivo*, which provides a higher prognostic result in production conditions.

N.P. Mazur *et al.* (2020) believe that the differential diagnosis of ovarian hypotrophy and hypoplasia is possible only by investigating pathological changes. According to their histological data the blood vessels were localised mainly in the area of the ovarian gate and around the vesicular follicles. Groups of blood vessels in ovarian hypoplasia, compared to hypofunction, were very weakly expressed, and collagen fibres were found in the vessel walls. The formation of collagen fibres in blood vessels can lead to a decrease in their elasticity, function, and nutrition of ovarian tissue. Such claims require additional research with comparisons of data using different methods.

In a range of studies, R. Alvarez *et al.* (2023) revealed patterns of functional asymmetry in the ovaries of heifers and cows, which was confirmed by the analysis of data using lateral fixation of palpable indicators. According to the researches of N. Mimoune *et al.* (2021) based on histological studies of the ovaries of cows with a permanent infertility due to anaphrodisia, it was found that 2-60% of lactating cows had a history of disorders in maintenance, keeping and feeding of heifers. Thus, by expanding the diagnostic capabilities of palpation examination of the ovaries, the possibility of the use of prophylactic and therapeutic schemes for stimulation and synchronisation of the sexual function of



heifers under commercial heifer rearing was increased. A. Channo *et al.* (2022) confirm the data on the increase in gynecological diseases, specifically, gonadopathies in both lactating cows and heifers during the cold transitional seasons of the year.

The researches show the way to optimise the conditions of keeping heifers of mating age, under which the most desirable morphometric parameters of the gonads during luteogenesis are observed, which determine the hormonal regulation of the formation of the muscular and mucous tissues of the uterus, resulting in increased survival of early embryos and pregnancy rate.

## CONCLUSIONS

Approximation of technological conditions for keeping of heifers of mating age to the naturally occurring biological requirements for the formation of animals in the environment will contribute to the development of high-quality gonads in terms of morphometric parameters, which will function according to the stages of the sexual cycle. This opens an additional biological resource for increasing the fertility rate of mating heifers, calf yields, and the planned rotation of primiparous cows into the dairy herd. These issues of industrial milk production are still highly relevant and need to be the right approach.

Studies using the modified palpation technique provided an additional resource for explication the morphometric and functional parameters of the gonads according to the lateral localisation of the luteal stage of the sexual cycle. The study confirmed the patterns of functional asymmetry of the ovaries of mating heifers as paired organs. The prevalence of hypotrophic phenomena in heifers of mating age is much more pronounced to the left, namely: 64.0% in the transitional seasons, 76.27% in the warm season.

Based on a year-long palpation examination of heifers of mating age ( $n=175$ ), it was found that on average 30.00% of ovaries had severe symptoms of hypotrophic changes in the absence of any morphological and functional structures on Days 7-9 of the sexual cycle; 33.33% – the presence of corpus luteum with signs of premature lysis due to hypotrophy; 33.34% –

ovaries had a functionally active corpus luteum with linear sizes within the species norms ( $P>0.05$ ). Significant seasonal dynamics of ovarian hypotrophy in heifers of mating age on Days 7-9 of the reproductive cycle was revealed: the highest rate of hypogonadism with the absence of morphofunctional corpus luteum was observed in transitional (spring, autumn) seasons – 66.67%, the lowest – in winter – 3.33%. It was experimentally established that signs of hypogonadism with symptoms of hypoluteogenesis and premature corpus lysis were found in transitional seasons (51.06), and the highest level of functional corpus luteum was observed in the summer season (41.24%), and specifically, the highest number of morphologically high-quality corpus luteum – 76.00%.

The effectiveness of artificial insemination of heifers of mating age of the experimental herd averaged 40.02% for the business year with minor seasonal fluctuations, which indicated a substantial effect of economic paratypical factors on the fertility of the heifers of mating age ( $P>0.05$ ). The use of a modified technique of differential palpation with a fixed examination period increases the predictability of diagnosis and selection of effective schemes for the prevention and treatment of hypotrophic ovarian pathologies and requires further research. The results confirm to the presence of a biological resource of generative and hormonal function in heifers of mating age of dairy breeds, which require detailed investigation to use the results to optimise hormonal and medicinal schemes for stimulation and synchronisation of the sexual cycle of the heifers of mating age under industrial housing technologies.

## ACKNOWLEDGEMENTS

The authors of this study would like to express their gratitude to the biotechnologists of the certified Embryo Transplantation Laboratory "PoltavaPlemServis" and personally to PhD in Agricultural Sciences S.O. Sidashova for contributing with technical support and ideas that made this study possible.

## CONFLICT OF INTEREST

The authors of this study declare no conflict of interest.

## REFERENCES

- [1] Alvarez, R.H., Duarte, K.M.R., Carvalho, J.B.P., Rocha, C.C., Junior, G.A.A., Trevisol, E., Melo, A.J.F., & Pugliesi, G. (2023). Ovarian morphology and follicular dynamics associated with ovarian aging in *Bos indicus* beef cow. *Animal Reproduction Science*, 254, article number 107279. doi: 10.1016/j.anireprosci.2023.107279.
- [2] Baban, O.A., Ordin, Yu.N., & Plahotniuc, I.N. (2021). *Histological changes in the ovaries of cows due to hypoplasia*. *International Scientific Journal "Endless Light in Science"*, 3(1), 87-94.
- [3] Bors, S.I., & Bors, A. (2020). Ovarian cysts, an anovulatory condition in dairy cattle. *The Journal of Veterinary Medical Science*, 82(10), 1515-1522. doi: 10.1292/jvms.20-0381.
- [4] Bors, S.I., Ibanescu, I., Creanga, S., & Bors, A. (2018). Reproductive performance in dairy cows with cystic ovarian disease after single treatment with buserelin acetate or dinoprost. *The Journal of Veterinary Medical Science*, 80(7), 1190-1194. doi: 10.1292/jvms.17-0690.
- [5] Borshch, O.O., Gutyj, B.V., Sobolev, O.I., Borshch, O.V., Ruban, S.Yu., Bilkevich, V.V., Dutka, V.R., Chernenko, O.M., Zhelavskiy, M.M., & Nahirniak, T. (2020). Adaptation strategy of different cow genotypes to the voluntary milking system. *Ukrainian Journal of Ecology*, 10(1), 145-150. doi: 10.15421/2020\_23.

- [6] Channo, A., Kaka, A., Kalwar, Q., Jamali, I., Jelani, G., Bakhsh, M., Dahri, G.N., & Goil, J.P. (2022). An overview of bovine cystic ovarian disease. *Pakistan Journal of Zoology*, 54(5), 2437-2444. doi: [10.17582/journal.pjz/20210905140956](https://doi.org/10.17582/journal.pjz/20210905140956).
- [7] Dhara, S., & Sharma, M. (2020). *Cystic ovarian disease in dairy cow*. *Theriogenology Insight*, 9(1), 1-8.
- [8] Dirandeh, E., & Ghaffari, J. (2018). Effects of feeding a source of omega-3 fatty acid during the early postpartum period on the endocannabinoid system in the bovine endometrium. *Theriogenology*, 121, 141-146. doi: [10.1016/j.theriogenology.2018.07.043](https://doi.org/10.1016/j.theriogenology.2018.07.043).
- [9] Donadeu, F.X., Sanchez, J.M., Mohammed, B.T., Ioannidis, J., Stenhouse, C., Maioli, M.A., Esteves, C.L., & Lonergan, P. (2020). Relationships between size, steroidogenesis and miRNA expression of the bovine corpus luteum. *Theriogenology*, 145, 226-230. doi: [10.1016/j.theriogenology.2019.10.033](https://doi.org/10.1016/j.theriogenology.2019.10.033).
- [10] European convention for the protection of vertebrate animals used for experimental and other scientific purposes. (1986). Retrieved from <https://rm.coe.int/168007a67b>.
- [11] Getahun, A.M., Hunderra, G.C., Gebrezihar, T.G, Boru, B.G., Desta, N.T., & Ayana, T.D. (2021). Comparative study on lesions of reproductive disorders of cows and female dromedary camels slaughtered at Addis Ababa, Adama and Akaki abattoirs with bacterial isolation and characterization. *BMC Veterinary Research*, 17, article number 134. doi: [10.1186/s12917-021-02822-z](https://doi.org/10.1186/s12917-021-02822-z).
- [12] Hryshchuk, H.P., Kovalyova, L.O., Huralaska, S.V., Yevtukh, L.G., & Kovalyov, P.V. (2023). Histological changes in the uterine and ovarian walls in pyometra. *Scientific Messenger of LNU of Veterinary Medicine and Biotechnologies. Series: Veterinary Sciences*, 25(109), 59-66. doi: [10.21521/mw.6234](https://doi.org/10.21521/mw.6234).
- [13] ISO/IEC 17025:2005. (2006). Retrieved from [http://online.budstandart.com/ua/catalog/doc-page.html?id\\_doc=50873](http://online.budstandart.com/ua/catalog/doc-page.html?id_doc=50873).
- [14] Jaśkowski, B.M. (2019). Corpus luteum with a cavity in cattle: An overview of past and present knowledge. *Veterinary Medicine- Science and Practice*, 75(6), 340-346. doi: [10.21521/mw.6234](https://doi.org/10.21521/mw.6234).
- [15] Law of Ukraine No. 249 "On the Procedure for Carrying out Experiments and Experiments on Animals by Scientific Institutions". (2012, March). Retrieved from <https://zakon.rada.gov.ua/laws/show/z0416-12#Text>.
- [16] Lima, F.S., Acosta, D.A., Egan, T.R., Skenandore, C., Sulzberger, S., French, D.D., & Cardoso, F.C. (2019). Steroidogenic, metabolic, and immunological markers in dairy cows diagnosed with cystic ovarian follicles at early and mid-late lactation. *Frontiers in Veterinary Science*, 6, article number 324. doi: [10.3389/fvets.2019.00324](https://doi.org/10.3389/fvets.2019.00324).
- [17] Ma, J., Burgers, E.E.A., Kok, A., Goselink, R.M.A., Lam, T.J.G.M., Kemp, B., & van Kneegsel, A.T.M. (2022). Consequences of extending the voluntary waiting period for insemination on reproductive performance in dairy cows. *Animal Reproduction Science*, 244, article number 107046. doi: [10.1016/j.anireprosci.2022.107046](https://doi.org/10.1016/j.anireprosci.2022.107046).
- [18] Mazur, N.P., Fedorovych, V.V., Fedorovych, E.I., Fedorovych, O.V., Bodnar, P.V., & Pakholkiv, N.I. (2020). Effect of morphological and biochemical blood composition on milk yield in Simmental breed cows of different production types. *Ukrainian Journal of Ecology*, 10(2), 61-67. doi: [10.15421/2020\\_110](https://doi.org/10.15421/2020_110).
- [19] Mimoune, N., Azzouz, M.Y., Khelef, D., & Kaidi, R. (2021). Ovarian cysts in cattle: A review. *Veterinary Sciences*, 52(5), 587-603. doi: [10.46419/vs.52.5.10](https://doi.org/10.46419/vs.52.5.10).
- [20] Peng, S.Y., Wu, T.H., Lin, T.Y., Hii, L.Y., Chan, K.S., Fu, T.Y., Chang, S.C., Shen, P.C., Liu, K.Y., & Shaw, S.W. (2020). Application of cattle placental stem cells for treating ovarian follicular cyst. *World Journal of Stem Cells*, 12(11), 1366-1376. doi: [10.4252/wjsc.v12.i11.1366](https://doi.org/10.4252/wjsc.v12.i11.1366).
- [21] Rottgen, V., Lapp, R., Viergutz, T., Weitzel, J.M., & Vernunft, A. (2020). Induction of cystic ovarian follicles (COFs) in cattle by using an intrafollicular injection of indomethacin. *The Journal of Reproduction and Development*, 66(2), 181-188. doi: [10.1262/jrd.2019-107](https://doi.org/10.1262/jrd.2019-107).
- [22] Sidashova, S.O. (2019). The influence of breed and technological factors on the fertilization of repair heifers with sex-sorted semen of Holstein bulls. *Cereal Crops*, 3(1), 163-170. doi: [10.31867/2523-4544/0075](https://doi.org/10.31867/2523-4544/0075).
- [23] Sidashova, S.O., Gutyj, B.V., Khalak, V.I., & Humeny, O.G. (2020). Influence of complex action of probiotic and specific prophylaxis of associated mucosal diseases on some quantitative traits of dairy cattle performance. *Scientific Messenger of Lviv National University of Veterinary Medicine and Biotechnologies. Series: Veterinary Sciences*, 22(97), 79-87. doi: [10.32718/nvlvet9714](https://doi.org/10.32718/nvlvet9714).
- [24] Szelényi, Z., Györi, D., Boldizsár, S., Kovács, L., Répási, A., Molnár, L., & Szenci, O. (2019). Pregnancy and stillbirth losses in dairy cows with singleton and twin pregnancies. *Acta Veterinaria Hungarica*, 67(1), 115-126. doi: [10.1556/004.2019.013](https://doi.org/10.1556/004.2019.013).
- [25] Yevtukh, L., Hryshchuk, H.P., Kovalchuk, Y., & Zaika, S. (2022). A histological pattern of the internal genitalia of cows with follicular ovarian cyst. *Scientific Messenger of LNU of Veterinary Medicine and Biotechnologies. Series: Veterinary Sciences*, 24(107), 119-124. doi: [10.32718/nvlvet10719](https://doi.org/10.32718/nvlvet10719).

## Динаміка гіпотрофічних змін морфологічних утворень яєчників телиць парувального віку на 7-9 день лютеогенезу

**Лілія Григорівна Роман**

Кандидат ветеринарних наук, доцент  
Одеський державний аграрний університет  
65012, вул. Пантелеймонівська, 13, м. Одеса, Україна  
<https://orcid.org/0000-0002-4983-5418>

**Віталій Андрійович Чорний**

Кандидат ветеринарних наук, доцент  
Одеський державний аграрний університет  
65012, вул. Пантелеймонівська, 13, м. Одеса, Україна  
<https://orcid.org/0000-0001-5705-1632>

**Ніна Іванівна Данкєвіч**

Кандидат ветеринарних наук, асистент  
Одеський державний аграрний університет  
65012, вул. Пантелеймонівська, 13, м. Одеса, Україна  
<https://orcid.org/0000-0001-8927-5219>

**Алла Павлівна Кітаєва**

Доктор сільськогосподарських наук, професор  
Одеський державний аграрний університет  
65012, вул. Пантелеймонівська, 13, м. Одеса, Україна  
<https://orcid.org/0000-0002-5990-9660>

**Олена Олександрівна Безалтична**

Кандидат сільськогосподарських наук, доцент  
Одеський державний аграрний університет  
65012, вул. Пантелеймонівська, 13, м. Одеса, Україна  
<https://orcid.org/0000-0002-4257-0699>

**Анотація.** Дослідження фізіологічного або патологічного стану яєчників корів та телиць в режимі реального часу *in vivo* є на сьогодні актуальними з причини того, що саме морфофункціональний стан гонад самиць великої рогатої худоби безпосередньо впливає на ефективність застосованих на практиці біотехнічних процедур: запліднення, стимуляцію та синхронізацію статевих функцій. Метою роботи було визначення кількісно-якісних показників морфофункціонального стану яєчників телиць української червоної молочної породи за перебігу господарського року за безприв'язного утримання в умовах промислового молочного комплексу. Впродовж дослідження було використано модифіковану диференційну діагностику морфометричного і функціонального стану яєчників у фіксований термін статевих циклу – з 7-го по 9-й день після овуляції домінуючого фолікулу (0-й день циклу). Для порівняння результатів трансректального обстеження телиць у різні сезони року було використано методику візуалізації пальпаторних даних *in vivo*. Було обстежено 175 голів телиць парувального віку, серед яких на 7-9-й день статевих циклу у 55,42 % встановлено пальпаторно жовте тіло яєчника відповідно стадії розвитку, у 26,96 % – передчасний лізис жовтого тіла, у 8,57 % – відсутність морфофункціональних утворень на поверхні яєчника, у 9,14 % – симптоми дегенеративних патологій гонад. В подальшому тварини з дегенеративними змінами яєчників (фолікулярна кістозність) не брали участь у дослідженні. Інші телиці мали яєчники з симптомами глибоких гіпотрофічних змін в тканинах (30,00 %) або ознаки передчасного лізису жовтого тіла (33,33 %). Впродовж господарського року відмічена виражена динаміка у наростанні або зниженні гіпотрофічних явищ в тканинах яєчників; найкращі показники морфометрії і функціональної активності телиць мали у теплий сезон, що свідчило за значний вплив на статеву функцію телиць парувального віку свіжого повітря і сонячної інсоляції. Було встановлено, що рівень заплідненості телиць впродовж року (в середньому 40,02 %) свідчив за наявність похибок у технології вирощування ремонтного поголів'я в умовах промислового підприємства. Отримані результати можуть бути корисні для оптимізації схем гормональної синхронізації статевих циклу ремонтних телиць та коректного добору гормональної терапії за симптомів зниження статевих активності.

**Ключові слова:** ремонтні телиці; статевий цикл; жовте тіло; морфофункціональний стан; поліморфізм; гіпогонадізм