

*Експериментальні статті*

UDC 616.34 – 008.89: 007.272: 636.1

**BAKHUR T., ANTIPOV A.**, candidates of vet. sciences'

*Bila Tserkva national agrarian university*

**ZGHOZINSKA O.**, cand. of vet. sciences'

*Zhitomyr National Agroecological University*

**PATHOMORPHOLOGICAL CHANGES IN THE LIVER AND INTESTINE OF HORSES WITH PARASCAROSIS AND STRONGYLATOSIS**

У результаті проведених досліджень були встановлені патоморфологічні зміни печінки, тонкого та товстого кишечника коней під впливом нематод. Виявлено, що ступінь прояву морфофункціональних змін залежить від інтенсивності інвазії та тяжкості патологічного процесу. У макро- і мікроскопічній будові печінки коней, уражених збудниками *Parascaris equorum* та *Strogylidae sp.*, спостерігали виражені зміни її гістоархітекtonіки (розлади мікрогемодинаміки, дискмплексація печінкових пластинок, набряклість цитоплазми гепатоцитів). Внаслідок гістологічних досліджень мікроструктури тонкого і товстого кишечника коней за параскарозної та стронгілятозної інвазій виявили запалення слизової оболонки, десквамацію епітелію кишкових ворсинок і крипт, крововиливи.

**Ключові слова:** параскароз, стронгілятози, десквамація, крововилив, набряк, паренхіма, гепатоцити.

**Problem statement.** The basis of the pathogenesis of helminthiasis of animals is a systemic violation of the morphofunctional activity of the gastrointestinal channel, which leads to a complex of pathological processes. Pathogenicity of helminths is associated with mechanical action, toxic effects, as well as inoculation and activation of pathogenic microorganisms [1, 2].

The type of helminths' pathological effect to the host's organism depends on many factors: species belonging, the intensity of the invasion, the place of localization, the biology of development and the physiological state of the animal [3, 4]. So, localizing in the intestine, worms *Parascaris equorum* and *Strogylidae sp.* can cause a violation of the blood-brain barrier, inflammatory reactions, hemorrhages in the body [5]. In addition, metabolites releasing by helminths, increase the permeability of the walls of capillaries. As a result, there is an accumulation of polymorphic cells in the inflammation center. At the same time, homeostasis is disturbed, pathological and compensatory processes are developing [6, 7].

However, it has been established that pathomorphological changes are registered not only in those organs where pathogen worms are localized, but also in other tissues and organs of the affected animals' body [8].

**Purpose of the article:** to study pathomorphological changes in the liver and intestines of horses with parascariosis and strongylatoses.

**Materials and methods of research.** In the conditions of the Zhytomyr meat-packing plant, we carried out the selection of slaughter material (liver and intestine samples) from 24 horses grown in the farms of Zhytomyr and Korosten' districts of Zhytomyr region. In the Zhytomyr meat-packing plant, we conducted a selection of slaughter material (samples of the liver and intestines) from 24 horses grown in farms of Zhytomyr and Korosten districts of Zhytomyr region. The horses that were selected for the study were mixed breeds, both sexes, 7–12 years old.

Before the slaughter of animals, a clinical and fecal examination was carried out. The results of a clinical study of animals showed no pathological changes in the general condition of animals.

The study of faeces was carried out by a flotation method using the solution of sucrose and Lugol fluid [9]. Standard Lugol solution (100 ml) contains iodine (1.0 g), potassium iodide (2.0 g) and glycerol (94.0 g). According to this method, 30 cm<sup>3</sup> of the flotation fluid (35% sugar solution and Lugol 1:5) with a specific weight of 1.15 was added to the sample of the test material (3,0 g). The mixture was filtered in a centrifuge tube and centrifuged for 5 minutes at 1500 rpm. To determine the generic and species belonging of the worm eggs, 3 drops of the surface of the solution at a small increase (× 120) were examined microscopically. We identified eggs by using an atlas of differential diagnosis of helminthiasis [10]. The study found that 6 of horses were free from parasitic worm, 10 of them had eggs *Parascaris equorum* + *Strogylidae sp.* in a faeces, 6 – eggs of *Strogylidae sp.* and 2 – just eggs of *Parascaris equorum*. The results of life-time helminthological research were confirmed by results of the post-mortem parasitology section. So, imagoes

of the corresponding nematodes were detected in the intestines of invasive animals. Healthy horses, free from nematodes invasion, became the control group.

Taking into account the absence of clinical signs of any diseases in horses, pathogens of other invasions or pathological changes not characteristic of helminthiasis, we determined that the animals we studied had no concomitant diseases.

For pathological and morphological studies, the slaughter, samples of organs were fixed in a 10% aqueous solution of neutral formalin (fixation time – 48 h). To neutralize formalin, calcium carbonate was used at a rate of 100 g per liter of formalin.

After fixation, the test material was washed with tap water. For this, bits of liver and intestine were placed in glass jars with apertures on the covers and placed in a sink under a small jet of water. The duration of flushing with running water was 24 hours.

The next stage in the manufacture of histological sections was the gradual dehydration of the washed material by ethyl alcohol with increasing concentration. For this, 50°, 70°, 80°, 90°, 96° and absolute alcohols were used. Dehydration period in spirits lasted 2–6 hours.

Subsequently, the pieces of the test material were transferred to a mixture of 96° alcohol and xylene (1:1) for 1 hour, and later to pure xylene for clarification. For making histological sections fixed pieces of organs were poured into paraffin. From each organ were made 4–5 paraffin blocks, which pasted on wooden bricks. From blocks on the snuff-microtubule MS-2 were made 3-4 histological sections (thickness up to 10 microns), which were glued to the substrate. The histological preparations stained with hematoxylinum of Karachi and eosin, and then they were placed into Canada balsam [10].

The time of painting the sections was 10–20 minutes. An overview and photograph of the histological preparations were performed using the Microscope Biolam C11 and Digital Camera Canon IXUS 75.

**Results and discussion.** As a result of the pathologic-anatomical autopsy, it was found that the liver of horses infested with mixed nematodes (parascariosis + strongylatosis) was slightly increased, flabby consistency and unevenly colored (from dark brown to light-clay color).

The liver of clinically healthy animals consists of connective tissue and parenchyma. The connective stroma is constructed of loose fibrous connective tissue and is represented by a capsule and trabeculae. The capsule covers the liver and tightly coupled with the serous membrane (visceral peritoneum). The liver lobes are polygonal and they are forming liver parenchyma. These lobes include the central vein, liver plates (beams), sinusoid hemocapillaries and gall bladder capillaries (Fig. 1). Central vein is located in the center of the lobe. Liver plates, formed by two rows of hepatocytes, are located radially from it. The microscopic structure of the liver of infected horses was affected (Fig. 2).

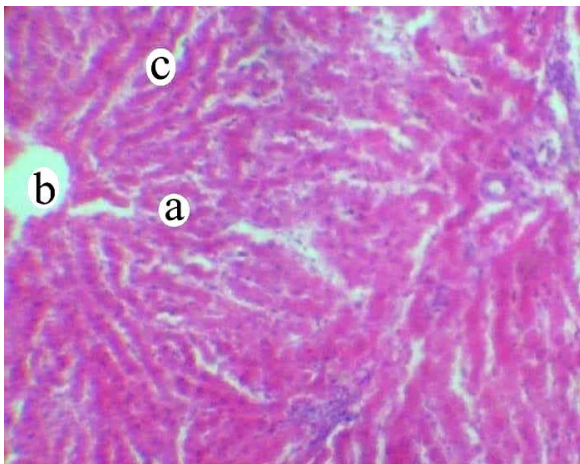


Fig. 1. Fragment of the microscopic structure of the liver of clinically healthy horses: a – liver lobe; b – central vein; c – liver plates. Hematoxylin Karatsi and eosin, × 56

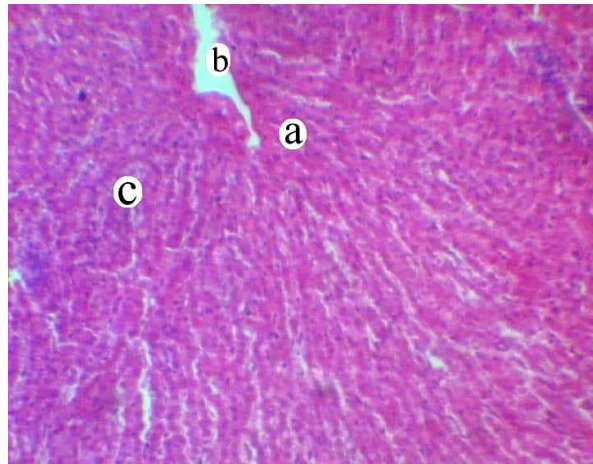


Fig. 2. Fragment of the microscopic structure of the liver of horses infected with *P. equorum* + *Strongylidae* sp.: a – hepatic lobe; b – central vein; c – liver plates. Hematoxylin Karatsi and eosin, × 56

The lobular structure of the organ was preserved, at the same time, the fuzzy separation of the parenchyma into the lobes was noted due to a small amount of round-cellular connective tissue (Fig. 3). In some infected horses, the boundaries between individual hepatic plates and liver cells were poorly expressed.

Hepatocytes are contoured, their cytoplasm is gently grainy, the nucleus is clear, located predominantly in the center of hepatocyte. However, in some sites, the dissection of the liver plates was detected. The central veins in such cases were not noticeable (Fig. 4).

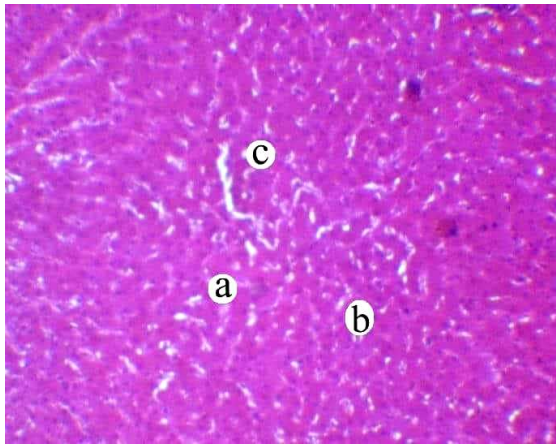


Fig. 3. Fragment of the microscopic structure of the liver of horses infected with *P. equorum* + *Strogylidae* sp.: a – hepatic lobe; b – hepatocytes; c – liver plates. Hematoxylin Karatsi and eosin, × 56

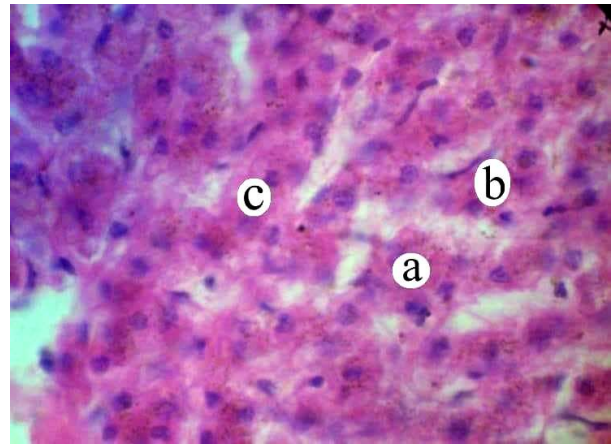


Fig. 4. A fragment of the microscopic structure of the liver of horses infected with *P. equorum* + *Strogylidae* sp.: a – hepatocytes; b – nuclei of hepatocytes; c – cytoplasm of hepatocytes. Hematoxylin Karatsi and eosin, × 120

Hepatocytes had a polygonal shape, well-painted nuclei. But often, as a result of stagnant phenomena in the liver of sick animals, hepatocyte cytoplasm was swollen.

During the examination of the intestines of affected animals were marked an inflammation of the duodenum and jejunum, point hemorrhages throughout its length. The vessels were blood-filled.

Histological examination of the colon of horses infected with *P. equorum* showed accumulation of lymphoid cells, eosinophils, in its own plate of the mucous membrane. Intestinal villi were in a state of slight edema. The superficial epithelium of the mucous membrane was desquamated (Fig. 5).

Morphological changes in the large intestine of horses indicated the development of inflammatory processes in it. So, macroscopically, local hyperemia of the serous membrane of the thick intestine was established. The mucous membrane had signs of catarrhal inflammation. Throughout the length of the cecum and colon, hemorrhages were detected. Separate vessels of the intestinal wall were enlarged and blood-filled.

During the histological examination of the colon in horses undergoing parasitic damage, it was found that the mucous membrane was infiltrated with a large number of erythrocytes, individual monocytes and lymphocytes.

The submucosa of the colon was slightly swollen and slightly infiltrated by lymphoid cells. A diffuse swelling of the muscular membrane is established. Also, desquamation of the epithelium of intestinal crypt and hemorrhage between fibers of the submucosal base was revealed (Fig. 6).

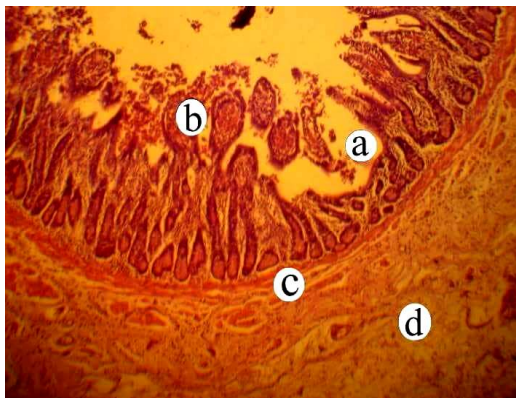


Fig. 5. Microscopic structure of the small intestine of horses infected with *P. equorum*: a – mucous membrane; b – intestinal villi; c – submucosal basis; d – muscle membrane. Hematoxylin Karatsi and eosin, × 56

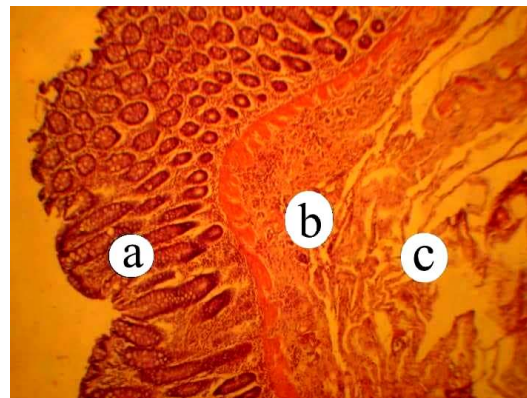


Fig. 6. Fragment of the microscopic structure of the large intestine of infected horses: a – mucous membrane; b – submucosal basis; c – muscle membrane. Hematoxylin Karatsi and eosin, × 56

Thus, our morphological studies gave grounds to assert that the macro- and microscopic structure of the liver, small and large intestines, because of parascariosis and strongylatoses invasion had pronounced changes in histoarchitectonic. These changes are characteristic for the development of the pathological process due to the effect on the organism of the horses of the parasites of the gastrointestinal tract.

**Conclusions.** 1. In the case of a mixed infection *P. equorum* + *Strogylidae* sp., in the liver of the horses, microhemodynamics disorders and compartmentalization of the liver plates were detected.

2. Histological studies of the microstructure of the small and large intestines of horses, patients with parascariosis and strongylatoses, revealed inflammation of the mucous membrane, desquamation of the epithelium of intestinal villus and crypts, hemorrhage between fibers of the submucosal basis.

#### LITERATURE

1. Ryabokon E. V. Manual of helminthiasis: for the students of medical faculty / E.V. Ryabokon, T.E. Onischenko, L.O. Ushenina et al // Zaporozhye: Zaporozhye State Medical University, 2013. – 66 p.
2. Lepri E. Pathology in Practice / E. Lepri, F. Beccati, A. Miglio et al. // Journal of the American Veterinary Medical Association, 2017. – Vol. 251. – No. 10. – P. 1153–1156.
3. Khurana S.K. Special Issue: Equine health, infectious diseases and zoonosis. / S.K. Khurana, K. Dhama, K. Karthik, M. Prasad / Journal of Experimental Biology and Agricultural Sciences, 2016. – V. 4. – No. 4 – P. 123–210.
4. Бахур Т.І. Порівняльна ефективність антигельмінтних препаратів для лікування коней за стронгілідозу / Т.І. Бахур, А.А. Антипов, В.П. Гончаренко та ін. // Проблеми зооінженерії та ветеринарної медицини: збірник наукових праць Харківської державної зооветеринарної академії, 2017. – В. 35. – Ч. 2. – Т. 2. – С. 27–31.
5. Khan M.A. Strongylosis in equines: a review / M. A. Khan, N. Roohi, M. A. A. Rana // The Journal of Animal & Plant Sciences, 2015. – No 25(1). – P. 1–9.
6. Lester S.J. Overview of Clinical Pathology and the Horse / S.J. Lester, W.H. Mollat, J.E. Bryant // Veterinary Clinics: Equine Practice, 2015. – Vol.31. – I.2. – P. 247–268.
7. Волков И.А. Патогистологические изменения пищеварительного канала лошадей и некоторые аспекты патогенеза при гастрофилезе / И.А. Волков // Рос. паразитол. журнал. – 2010. – № 2. – С. 71–77.
8. Згозінська О.А. Патоморфологія печінки коней, інвазованих збудниками параскарозу та стронгілятозів / О.А. Згозінська // Проблеми зооінженерії та ветеринарної медицини: збірник наукових праць Харківської державної зооветеринарної академії, 2017. – В. 35. – Ч. 2. – Т. 2. – С. 55–58.
9. Пат. на корисну модель № 66145, Україна, МПК (2011.01) u 2011 06852, A61D 99/00. Спосіб копрологічної діагностики гельмінтозів і еймеріозів / Довгий Ю.Ю., Фешченко Д.В., Корячков В.А., Згозінська О.А., Бахур Т.І., Драгалчук А.І., Стахівський О.В.; заявник і патентовласник Житомирський національний агроекологічний університет. – заявл. 31.05.2011; опубл. 26.12.2011, Бюл. 24.
10. Атлас гельмінтів тварин / І.С. Дахно, А.В. Березовський, В.Ф. Галат [та ін.] – К.: Ветінформ, 2001. – 118 с.
11. Горальський Л.П. Основи гістологічної техніки і морфофункціональні методи дослідження у нормі та при патології: навч. посібник / Л.П. Горальський, В.Т. Хомич, О.І. Кононський – Житомир: Полісся, 2005. – 288 с.

#### REFERENCES

1. Ryabokon, E.V., Onischenko, T.E., Ushenina, L.O., Furyk, E. A., Mashko, O. P. (2013), *Manual of helminthiasis: for the students of medical faculty*, Zaporozhye: Zaporozhye State Medical University, 66 p.
2. Lepri, E., Beccati, F., Miglio, A., Passamonti, F., Veronesi, F., Mandara, M.T. (2017), "Pathology in Practice", *Journal of the American Veterinary Medical Association*, Vol. 251, No. 10, pp. 1153-1156.
3. Khurana, S. K., Dhama, K., Karthik, K., Prasad, M. (2016), "Special Issue: Equine health, infectious diseases and zoonosis", *Journal of Experimental Biology and Agricultural Sciences*, V. 4, No. 4, pp. 123-210.
4. Bakhur, T.I., Antipov, A.A., Goncharenko, V.P., Artemenko, L.P., Avramenko, N.V., Solovyova, L.M., Koziy, N.V., Shahanenko, V.S., Pidborska, R.V. (2017), "Comparative effectiveness of antihelminthic drugs for the treatment of horses with stronhillidiosis" ["Porivnyal'na efektyvnist' antyhel'mintnykh preparativ dlya likuvannya koney za stronhilydozu"], *Problems of zoinengineering and veterinary medicine: a collection of scientific works of the Kharkiv State Animal Veterinary Academy*, V. 35(2), No 2, pp. 27-31.
5. Khan, M.A., Roohi, N., Rana, M.A.A. (2015), "Strongylosis in equines: a review", *The Journal of Animal & Plant Sciences*, No 25(1), pp. 1-9.
6. Lester, S.J., Mollat, W.H., Bryant, J.E. (2015), "Overview of Clinical Pathology and the Horse", *Veterinary Clinics: Equine Practice*, Vol. 31, I. 2, pp. 247-268.
7. Volkov, I.A. (2010), "Pathogistological changes in the digestive tract of horses and some aspects of pathogenesis in gastrofiliosis" ["Patogistologicheskiye izmeneniya pishchevaritel'nogo kanala loshadey i nekotoryye aspekty patogeneza pri gastrofileze"], *Russian Parasitological Journal*, No. 2, pp. 71-77.
8. Zghozinska, O.A. (2017). "Pathomorphology of the liver of horses infested by pathogens of parascariosis and strongylatosis", ["Patomorfolohiya pechinky koney, invazovanykh zbudnykamy paraskarozu ta stronhilyatoziv"], *Problems of zoinengineering and veterinary medicine: a collection of scientific works of the Kharkiv State Animal Veterinary Academy*, V. 35(2), No 2, pp. 55-58.
9. Dovgij, Yu.Yu., Feshchenko, D.V., Koryachkov, V.A., Zghozinska, O.A., Bakhur, T.I., Dragalchuk, A.I., Stakhivsky, O.V (2011), *Sposib koprohichnoyi diahnozyky hel'mintoziv i eymerioziv* [Method of coprological diagnosis of helminthiasis and eumerioses]. Patent for Utility Model, Ukraine, No. 66145.



10. Dakhno, I.S., Berezovsky, A.V., Galat V.F. et al (2001), *Atlas of helminths of animals [Atlas hel'mintiv tvaryn]*, Vetinform, Kyiv, 118 p.

11. Goralsky, L.P., Khomich, V.T., Kononsky, O.I. (2005), *Fundamentals of histological technique and morphofunctional methods of research in norm and at pathology: a manual [Osnovy histolohichnoyi tekhniki i morfofunktsional'ni metody doslidzhennya u normi ta pry patolohiyi: navchal'nyu posibnyk]*, Zhytomyr: Polissya, 288 p.

**Патоморфологические изменения в печени и кишечнике лошадей, больных параскарозом и стронгилятозами  
Бахур Т.И., Антипов А.А., Згозинская О.А.**

В результате проведенных исследований были установлены патоморфологические изменения печени, тонкого и толстого кишечника лошадей под влиянием нематод. Выявлено, что степень проявления морфофункциональных изменений зависит от интенсивности инвазии и тяжести патологического процесса. В макро- и микроскопическом строении печени лошадей, пораженных возбудителями *Parascaris equorum* и *Strogylidae sp.*, наблюдали выраженные изменения ее гистоархитектоники (расстройства микрогемодинамики, дисконкомплексация печеночных пластинок, отечность цитоплазмы гепатоцитов). Вследствие гистологических исследований микроструктуры тонкого и толстого кишечника лошадей при параскарозной и стронгилятозной инвазий выявляли воспаление слизистой оболочки, десквамацию эпителия кишечных ворсинок и крипт, кровоизлияния.

**Ключевые слова:** параскароз, стронгилятозы, десквамация, кровоизлияние, отек, паренхима, гепатоциты.

**Pathomorphological changes in the liver and intestine of horses with parascariosis and strongylatoses**

**Bakhur T.I., Antipov A.A., Zghozinska O.A.**

As a result of the conducted research, pathomorphological changes of the liver, small and large intestines of horses under the influence of nematodes were established. It was found that the degree of manifestation of morphofunctional changes depends on the intensity of the invasion and severity of the pathological process. In the macroscopic and microscopic structure of the liver of horses, infected by *Parascaris equorum* та *Strogylidae sp.*, histoarchitectonic changes were observed (microhemodynamics disorders, dysplasia of liver plates, swelling of the hepatocytes' cytoplasm). Due to histological studies of the microstructure of the small and large intestines of horses with parascariosis and strongylatoses, inflammation of the mucous membrane, desquamation of the epithelium of the intestinal villi and crypts, hemorrhages were revealed.

**Keywords:** parascariosis, strongylatoses, desquamation, hemorrhage, edema, parenchyma, hepatocytes.